

# The Role of Orthognathic Surgery in Management of Gingival Fibromatosis, Technical Note

Amin Rahpeyma, Saeedeh Khajehahmadi\*

Oral and Maxillofacial Diseases Research Center, School of Dentistry, Mashhad University of Medical Sciences, Mashhad, Iran.

## Abstract

Sever gingival fibromatosis may cause bimaxillary dentoalveolar protrusion. In these patients, multidisciplinary approaches by collaboration within several specialists, orthodontics, periodontics, and oral & maxillofacial surgeons is mandatory to obtain a good result. Orthognathic surgery can be used to correct dentofacial deformity that has positive effects on facial esthetic in some selected cases of gingival fibromatosis. This article recommends solutions for the problems during orthognathic surgeries that are unique to these patients.

*Key words: Gingival fibromatosis, Orthognathic surgery, Facial deformity*

## Introduction

Gingival fibromatosis is a slowly progressive gingival enlargement with the prevalence of one per 175000 populations and equal distribution in sexes [1]. It also has been called elephantiasis gingiva, diffuse fibroma, familial elephantiasis, idiopathic fibromatosis, hereditary gingival fibromatosis, and congenital familial fibromatosis. Gingival fibromatosis may be familiar or idiopathic, that can occur in soft tissue or bone. The familiar variant happened as an isolated or association with syndromes such as Zimmermann-Laband, Murray-Puretic-Drescher, Rutherford, Multiple hamartoma, Cross, Ramon, Jones, and Prune belly. The diagnosis is based on clinical feature, histopathological view, and family history. The treatment dependent on the severity of the gingival overgrowth. In scanty enlargements, scaling and proper oral hygiene may be sufficient. The surgical management of the gingival overgrowth in these patents mainly is gingivectomy [2]. Dentofacial structures can be affected in some cases, so orthognathic surgery may have beneficial effects [3]. In current treatment plan, orthognathic surgery is not applied frequently in gingival fibromatosis patients.

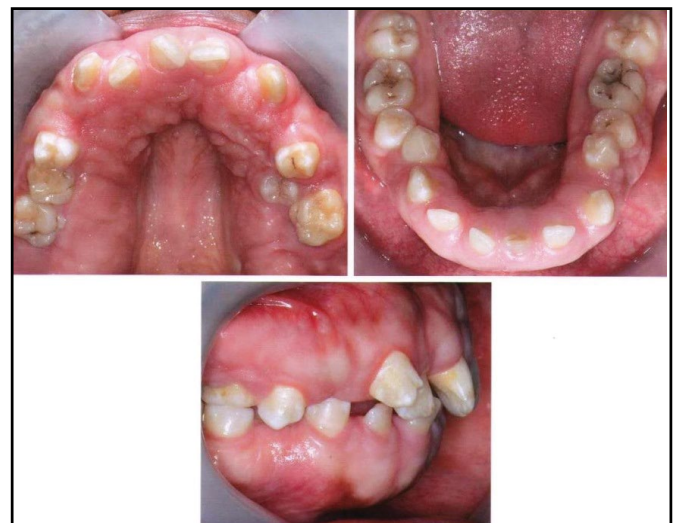## Patient and Surgical Techniques

A 24 years old girl was referred to the Department of Oral and Maxillofacial Surgery, University of Mashhad, Mashhad, Iran for consultation about protruding jaws. Both jaws were protruded forward and the lips cannot reach together without tension. Intraoral examination revealed pink and firm overgrowth gingiva, which displaced and rotated the anterior teeth. There was large diastema between the anterior teeth. Maxillary right premolar and all wisdom teeth were impacted. Maxillary left permanent molar had been extracted during childhood. Mandibular anterior teeth had spacing, and the firm gingiva exists up to half of the clinical crown (*Figure 1*).

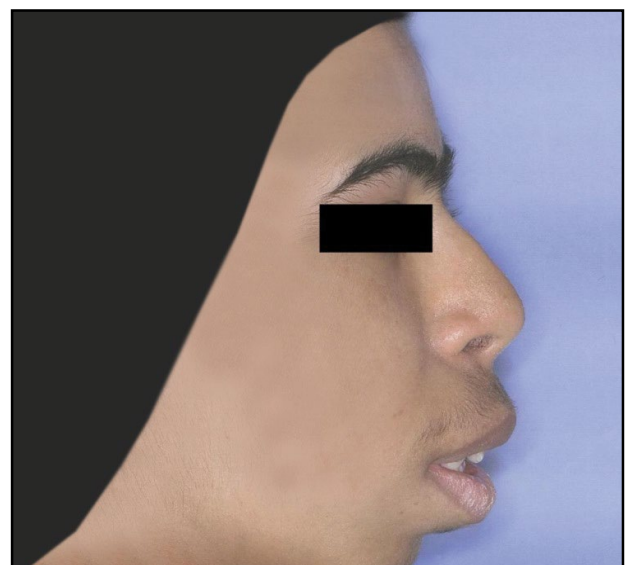
There was any sign of hirsutism. The patient was not mental retard who has familiar variant of gingival fibromatosis with an isolated finding (non syndromic variant). The father, an aunt, and all sisters suffered from gingival fibromatosis. The gingival enlargement was generalized. Based on clinical and radiographic findings the diagnosis of the patient was class I bimaxillary dentoalveolar protrusion. Maxillary left I

setback in posterior and superior direction, mandibular set back via bilateral sagittal osteotomy technique and advancement genioplasty were done.

Pre and post-operative photographs and lateral cephalographs are illustrated at *Figure 2*.



*Figure 1. Gingival overgrowth with displacement and rotation of the teeth and diastema.*



*Figure 2a. Clinical picture; Protruded lips and lip incompetence.*



orthodontics and periodontics while oral and maxillofacial surgical presiders is trimmed.<sup>10-13</sup> However orthognathic surgery also can be helpful in some selected cases. Since the gingival overgrowth can affect underlying bone, the thickness of the alveolar bone will increase and both jaws may be positioned anteriorly. Since Protruding jaws generally had social effect on the patients, so balanced face cannot achieve without orthognathic surgery.

Because of the insufficient clinical crown of the teeth to bracket attachment, Orthodontic preparation before surgery was impossible in the presented case. The problems of the orthognathic surgical techniques in this special patient are listed below and solutions are presented:

1. It was impossible to use arch bars so ivy loop wiring between mandibular molars and IMF screws in maxilla and anterior mandible were applied to achieve maxillomandibular fixation.

2. Too thick maxillary bone walls makes maxillary down fracturing more difficult. Placing osteotomy anterior to the pterygoid process instead of the pterygomaxillary separation by osteotome is the way to reduce complications.

## References

1. Kather J, Salgado MAC, Salgado UFL, Cortelli JR, Pallos D. Clinical and histomorphometric characteristics of three different families with hereditary gingival fibromatosis. *Oral Surgery, Oral Medicine, Oral Pathology, Oral Radiology and Endodontology*. 2008; **105**: 348–352.
2. Dhadse PV, Yeltiwar RK, Pandilwar PK, Gosavi SR. Hereditary gingival fibromatosis. *Journal of Indian Society of Periodontology*. 2012; **16**: 606-609.
3. Aghili H, Goldani Moghadam M. Hereditary gingival fibromatosis: a review and a report of a rare case. *Case Reports in Dentistry*. 2013; 930972.
4. Prasad SS, Radharani C, Sinha S, Kumar SK. Hereditary gingival fibromatosis with distinctive facies. *The Journal of Contemporary Dental Practice*. 2012; **13**: 892-896.
5. Bansal A, Narang S, Sowmya K, Sehgal N. Treatment and two-year follow-up of a patient with hereditary gingival fibromatosis.

3. Maxillary buccal overgrowth makes difficulty in medial cut of mandibular ramus sagittal osteotomy. Small bend malleable retractor should be used instead of channel retractor. Pubmed search with gingival fibromatosis and orthognathic surgery was positive for one previous case with Zimmermann-Laband syndrome [10]. The present case in this article recommended solutions for the problems during orthognathic surgeries that are unique to these patients.

## Conclusion

To conclude, this article recommends that orthognathic surgery can be used for correction of dentofacial deformity that has positive effects on facial esthetic in the some selected cases of the gingival fibromatosis.

## Acknowledgment

This study was supported by a grant from the Vice Chancellor of Research of Mashhad University of Medical Sciences.

## Conflict of Interest

None declared.

*Journal of Indian Society of Periodontology*. 2011; **15**: 406-409.

6. Häkkinen L, Csiszar A. Hereditary gingival fibromatosis: characteristics and novel putative pathogenic mechanisms. *Journal of Dental Research*. 2007; **86**: 25–34.

7. Hart TC, Pallos D, Bowden DW, Bolyard J, Pettenati MJ, Cortelli JR. Genetic linkage of hereditary gingival fibromatosis to chromosome 2p21. *The American Journal of Human Genetics*. 1998; **62**: 876–883.

8. Xiao S, Bu L, Zhu L, Zheng G, Yang M, Qian M, et al. A new locus for hereditary gingival fibromatosis (GINGF2) maps to 5q13-q22. *Genomics*. 2001; **74**: 180–185.

9. Ye X, Shi L, Cheng Y, Peng Q, Huang S, Liu J, et al. A novel locus for autosomal dominant hereditary gingival fibromatosis, GINGF3, maps to chromosome 2p22.3-p23.3. *Clinical Genetics*. 2005; **68**: 239–244.

10. Perks T, Popat H, Cronin AJ, Durning P, Maggs R. The orthodontic and surgical management of Zimmermann-Laband syndrome. *Orthodontics (Chic.)* 2013; **14**: e168-176.