

A Single Injection Straight Line Approach to Anesthetize Inferior Alveolar Nerve, Long Buccal Nerve and Lingual Nerve: A New Technique

Ahmed Suhael, Tabassum Nafeesa, youssef Sara, Al dayel Omar

Riyadh College of Dentistry and Pharmacy, Riyadh, Kingdom of Saudi Arabia

Abstract

Pain management is central to the success of any dental procedure. Many patients choose their dentist based on perceived ability of the dentist to deliver painless dentistry. Inferior alveolar nerve block is the most commonly employed nerve block in mandibular region. Although several techniques for inferior alveolar nerve block have been advocated by various authors, effective anesthesia of the inferior alveolar nerve on a consistent basis is never an easy task particularly for inexperienced dentists. The difficulty usually LIES in the accurate localization of anatomical landmarks particularly the pterygomandibular raphe. It is also a known fact that mandibular anesthetic techniques present a lower success rate when compared to maxillary anaesthetic techniques due to greater density of the mandibular alveolar bone, limited access to the inferior alveolar nerve, marked anatomical variations, and need for deeper needle penetration into the soft tissue. Unfortunately, this nerve block has a comparatively high failure rate.

In this article, we present a modification of the conventional inferior alveolar nerve block technique which is simple, easy to master, has high success rate and comfortable to patients as multiple needle penetrations are avoided. In the standard technique, following anesthesia of inferior alveolar nerve, the needle is redirected for lingual nerve anesthesia leading to potential complications which is avoided in single injection straight line technique. A clinical study of alternative inferior alveolar nerve block along with long buccal and lingual nerve blocks, by injecting local anesthesia into the pterygomandibular space by single penetration without redirecting the needle was performed on two hundred and seven patients undergoing simple extractions and surgical extractions of mandibular molars. A success rate of 97.5% was obtained.

Key Words: *Conventional inferior alveolar nerve block, Alternative technique, Straight line technique, Single injection technique, Local anesthesia*

Introduction

The technique most commonly used for anesthesia of the inferior alveolar nerve is the traditional Halsted method [1], a direct technique in which the inferior alveolar nerve is reached by an intraoral approach before it enters the mandibular canal. This technique has success rates from 71 to 87 percent. Some investigators reported that success rates for alternative blocks are higher than those reported for Inferior alveolar nerve block [2].

Sandoval et al in 2008 conducted a pilot study of inferior alveolar nerve block anesthesia via retromolar triangle in patients in the age range of 40 to 60 years to ascertain if the anesthesia administered was sufficient to carry out surgery. The technique proved to be ineffective in 25 percent of the cases [3].

Galdames et al (2008) suggested an anesthetic technique for the inferior alveolar, buccal and lingual nerves, using retromolar trigone as reference. They recommended this technique for patients with blood dyscrasias, but found to be less effective than the conventional inferior alveolar nerve block technique [4].

Many authors have contributed to improve the anesthesia of inferior alveolar nerve, refining and creating new techniques to enhance the success rate of the technique [5-10].

In this study, we analyse the efficiency of an alternative inferior alveolar nerve block technique, using anatomical reference points that are easily observed during application of anesthesia, simplifying the learning process and consequently

increasing the success rate.

Materials and Methods

This study followed the declaration of Helsinki on medical protocol and ethics. The Ethical Review Committee of Riyadh College of Dentistry and Pharmacy has approved the study (No. FRP/2012/6).

After obtaining consent from patients in Riyadh college of dentistry and pharmacy, patients were administered inferior alveolar nerve block, lingual nerve block and long buccal nerve block using 'Single injection straight line technique'.

A prospective randomized analytical study was conducted in two hundred and seven patients undergoing simple extraction of mandibular molar teeth and surgical removal of impacted mandibular molars. The group included hundred and thirty eight male and sixty nine female patients in the age range of 25-55 years.

Exclusion criteria

- Patients with bleeding disorders.
- Patients on aspirin therapy.
- Patients with history of allergy to local anesthetics.
- Patients with missing reference teeth.

Anatomical review

Understanding the anatomy is a pre requisite for successful anesthesia. The inferior alveolar nerve emerges below the lower head of the lateral pterygoid muscle and curves down on medial pterygoid muscle. The nerve lies anterior to its vessels between the sphenomandibular ligament and the ramus of the

mandible, before entering the mandibular foramen. It is into this region, just above the foramen, the anaesthetic solution is introduced for conventional inferior alveolar nerve block. The lingual nerve appears below the lateral pterygoid on the wall of the pharynx and passes forwards and downwards between the medial pterygoid and the mandible. It curves down on the medial pterygoid about 1 cm in front of the inferior alveolar nerve [11].

The buccal nerve passes between the two heads of the lateral pterygoid and courses downwards and forwards in a fascial tunnel on the deep surface of temporalis. It runs on the buccinator, giving off branches to the skin over the cheek, pierces the buccinator and supplies the mucous membrane of the cheek and gingiva of the lower molars [11].

On palpating the ramus of the mandible, several bony landmarks are apparent. On the anterior border of the ramus, the more significant landmark is the coronoid notch, the point of greatest concavity. The coronoid notch gives an indication of the position of mandibular foramen, as the notch and the foramen are usually along the same plane although there may be variations with age changes, with the foramen being more superiorly placed in edentulous and more inferiorly placed in children.

Anatomical landmarks used for this technique are anterior border of ramus, coronoid notch, posterior border of ramus, buccal mucosa distal to mandibular third molar and occlusal plane (Figures 1 and 2).

Nerve block technique

Operator position was at 8 o'clock and 11 o'clock for the right and left side of the mandible respectively. Patient being seated in a semisupine position, coronoid notch on the anterior border of ramus was palpated using thumb. This was done by moving the thumb along the anterior border of ramus with the patient's neck extended. The thumb was firmly placed on the coronoid notch to help the clinician gauge the location for deposition of anesthesia. Simultaneously the index finger of the same hand is placed on the posterior border of the mandible extra orally. The mandibular foramen is located approximately between the anterior and posterior border of ramus, that is between thumb and the index finger.

Maximal mouth opening as in standard inferior alveolar nerve block is not recommended. When mouth is opened too wide, the inferior alveolar nerve is approximated too closely to the medial aspect of ramus. In this technique, the

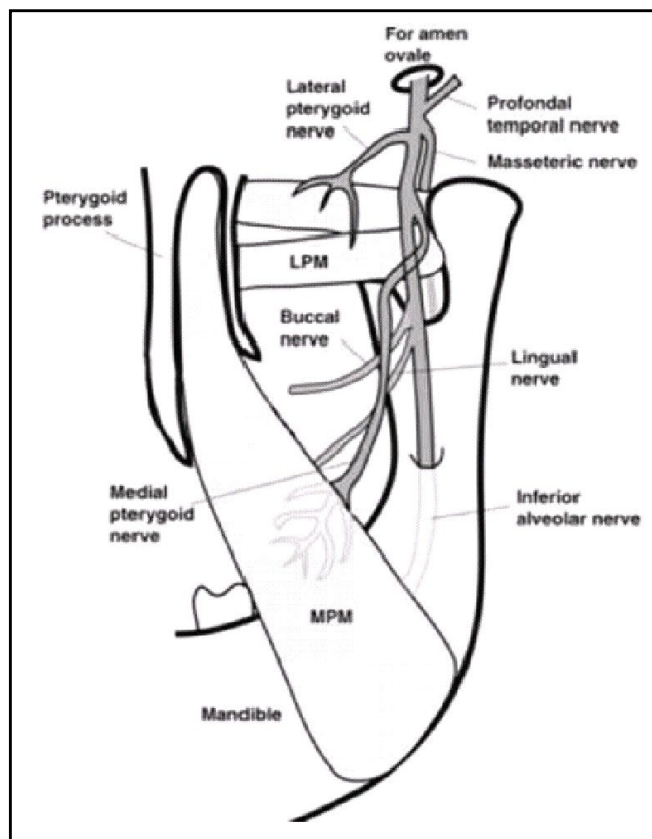


Figure 2. Nerves to be anesthetized: Inferior alveolar nerve, Lingual nerve and long buccal nerve are shown. (MPM- Medial pterygoid muscle) (LPM: Lateral Pterygoid Muscle).

mouth should be opened wide enough only for the operator to comfortably inject local anesthesia, at the same time ensuring the nerve is away from the medial aspect of ramus and close to the area of deposition of anesthetic solution.

Area of needle insertion

Using a 27 gauge needle, buccal mucosa was pierced 1 cm distal to mandibular third molar antero posteriorly and 1cm away from the thumb medially. The target area for deposition of local anesthesia in the 'Single injection straight line technique' was inferior alveolar nerve adjacent to the mandibular foramen. With the mouth half open, the needle was advanced along a straight line aligning the disto incisal surface of mandibular lateral incisor on ipsilateral side of injection. The needle bisected the middle of the thumb of left hand which is stationary on coronoid notch, parallel to and about 5mm above the occlusal plane. Needle was advanced until about 2/3rds of the needle was within the tissue. Following aspiration, 1.2 ml anesthetic solution was slowly deposited to anesthetise inferior alveolar nerve. Since the success of nerve block was not related to the bevel orientation, facing the bevel of the needle towards the bone was not considered in this technique [12]. Half the length of the needle was withdrawn and the syringe was aspirated and 0.4 ml was deposited for anesthesia of lingual nerve. After withdrawing the needle further to an extent that only 1/4th of the needle was inside the tissue, the remaining 0.2 ml solution was deposited for anesthesia of the long buccal nerve (Figure 3 and 4).

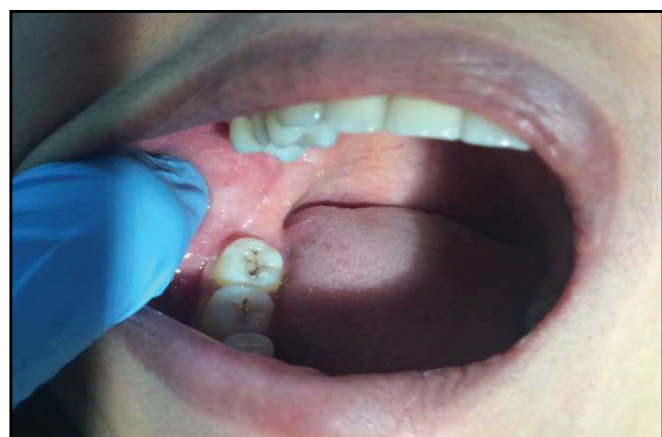

Figure 1. Coronoid notch: Thumb placed on the Coronoid notch, the greatest depth of anterior border of ramus.

Results

Out of two hundred and seven patients who were included

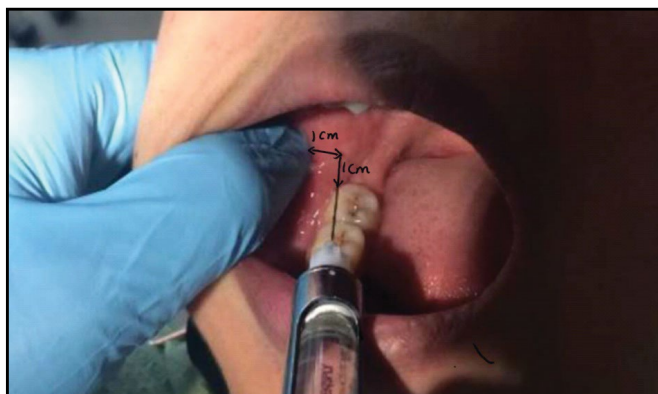

Figure 3. Needle position: The straight line shows the orientation of needle extending along the mandibular lateral incisor tooth on the ipsilateral side.

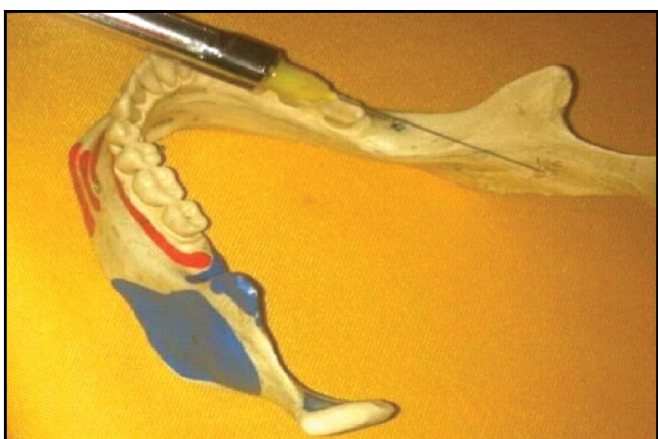


Figure 4. Needle position: The straight line shows the orientation of needle extending along the mandibular lateral incisor tooth on the ipsilateral side.

in the study, anesthesia was successful in two hundred and two patients. The remaining 5 patients needed to be given a second cartridge of anesthesia after it was found that the first cartridge did not achieve desired anesthesia. Success rate in this study was 97.5 percent.

After 2 minutes following deposition of anesthetic solution, the onset of anesthesia was evaluated by assessing the subjective symptoms in the patient for numbness on lower lip and tip of the tongue followed by probing the tissues innervated by buccal, lingual and inferior alveolar nerves and efficacy of anesthesia was recorded. Onset of anesthesia was achieved in 2 min in 202 patients (score 0), score 1 in 3 patients, score 2 in one patient and score 3 in one patient (Chart 1).

Discussion

In 1884, William S. Halsted and Richard J. Hall first achieved neuroregional anesthesia in the mandible by injecting a solution of cocaine in the vicinity of the mandibular foramen [13]. Since that revolutionary injection, dentists have improvised periodically to deliver invasive dental treatment in a pain-free manner aimed at relieving sufferings of patients.

To achieve mandibular anesthesia, most dentists in the United States use an injection technique targeting the mandibular sulcus, similar to the technique described by Jorgensen and Hayden in 1967 [14]. This injection remains a proven method for delivering local anesthesia in a safe manner with minimal discomfort to the patient, and it usually represents one of the first clinical skills students learn in dental school.

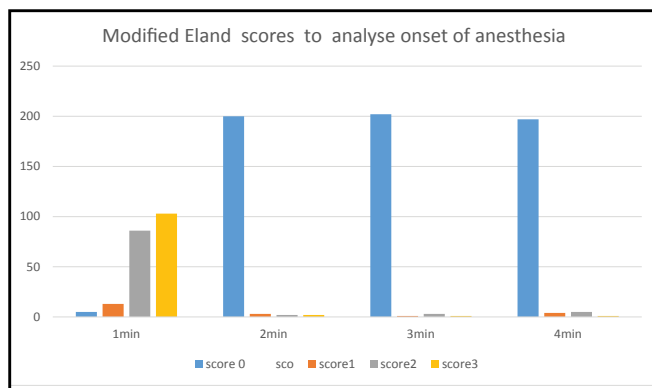


Chart 1. Vertical axis – number of patients; Horizontal axis –onset of anaesthesia; score 0-no pain; score 1-hurts a little; score 2-hurts but less than the most painful event; score 3-hurts the most.

However, a limitation of the classical inferior alveolar nerve block is that it relies on the presence and identification of anatomical landmarks such as the pterygomandibular raphe and the retromolar pad. Although the importance of these landmarks cannot be overlooked, the localisation of particularly the pterygomandibular raphe may not be as easy for beginners. Malamed identifies the inferior alveolar nerve block as the injection with highest clinical failure rate, which he reports to be 15 to 20 percent when properly administered². This high failure rate is often attributed to a high degree of variation in the morphology of the mandibular ramus and the location of the mandibular foramen, however improper technique still remains the most common reason for failure [15].

In the 1970s two alternatives to the standard Inferior Alveolar nerve block were introduced. In 1973, George A.E. Gow-Gates described a novel approach to mandibular anesthesia in which the anesthetic solution is injected just anterior to the head of the mandibular condyle at maximal opening [16]. Watson and Gow-Gates reported that this mandibular block technique consistently yields a higher percentage of clinically excellent anesthesia than do conventional techniques [8]. A recognized disadvantage of the Gow-Gates technique is slower onset of anesthesia, which can take from five to seven minutes [1]. Also a lack of definite anatomical landmarks makes it difficult to master it easily and has frequently been a second choice anesthesia after failure of conventional Inferior alveolar nerve block.

In 1977, Akinosi introduced a closed mouth approach for mandibular anesthesia. This technique is indicated in trismus patients. Rapid induction of anesthesia represents another advantage of the Akinosi technique. The advantages associated with the Gow-Gates and Akinosi techniques make them attractive to minimize patient discomfort and anxiety. Despite the advantages, some clinicians may avoid these techniques out of fear of increasing pain associated with the injection. However, multiple randomized controlled clinical trials have found no significant differences in pain on injection among the three techniques (standard inferior alveolar nerve block, Gow-Gates mandibular block, and Akinosi mandibular block) [17,18].

Perceived increased risk represents other reason clinicians may reject the alternative techniques. Few authors fervently oppose the widespread use of Akinosi and Gow-Gates Techniques [19]. Isolated cases of temporary paralysis of

cranial nerves III, IV, and VI following the Gow-Gates mandibular block have also been reported [20,21].

In the "Single injection straight line technique" described, a significant advantage is that along with inferior alveolar nerve and lingual nerve, it blocks the long buccal nerve, obviating the need for a separate injection. Maneuvering the needle inside the tissue for anesthetising the lingual nerve as is done in the conventional technique is not required as the lingual nerve is just about 1cm anterior to inferior alveolar nerve and deposition of anesthesia anterior to inferior alveolar nerve ensures deposition of anesthesia in the vicinity of the lingual nerve [11]. Long buccal nerve is located further

anteriorly corresponding to the straight line from mandibular lateral incisor to the distal aspect of mandibular third molar.

As in case of classical inferior alveolar nerve block where mouth is opened wide in order to ensure the nerve lies closer to the medial aspect of ramus, we do not recommend opening the mouth wide in this technique.

Conclusion

In the technique described, the anatomical landmarks are definite points such as coronoid notch and occlusal plane, and syringe is advanced in a straight line. This makes it relatively easy for the clinician to master the technique.

References

1. Malamed SF. The Gow-Gates mandibular block: evaluation after 4275 cases. *Oral Surgery, Oral Medicine, Oral Pathology*. 1981; **51**: 463-7.
2. Sisk AL. Evaluation of the Gow-Gates mandibular block for oral surgery. *Anesthesia Progress*. 1985; **32**: 143-146.
3. Sandoval MC, Suazo GI, Cantin LM, Lopez FB. Pilot study of Inferior alveolar nerve block anesthesia via retromolar triangle in patients of 40 to 60 years. *International Journal of Odontostomatology*. 2008; **2**: 20.
4. Suazo Galdames IC, Contín López MG, Zavando Matamala DA. Inferior alveolar nerve block anesthesia via the retromolar triangle, an alternative for patients with blood dyscrasias. *Medicina Oral Patología Oral y Cirugía Bucal*. 2008; **13**: E43-7.
5. Gow-Gates GA. Mandibular conduction anesthesia: a new technique using extraoral landmarks. *Oral Surgery, Oral Medicine, Oral Pathology*. 1973; **36**: 321-8.
6. Gustainis JF, Peterson LJ. An alternative method of mandibular nerve block. *Journal of the American Dental Association*. 1981; **103**: 33-6.
7. Malamed SF. The periodontal ligament (PDL) injection: an alternative to inferior alveolar nerve block. *Oral Surgery, Oral Medicine, Oral Pathology*. 1982; **53**: 117-121.
8. Watson JE, Gow-Gates GA. A clinical evaluation of the Gow-Gates mandibular block technique. *The New Zealand Dental Journal*. 1976; **72**: 220-3.
9. Aggarwal V, Jain A, Kabi D. Anesthetic efficacy of supplemental buccal and lingual infiltrations of articaine and lidocaine alter an inferior alveolar nerve block in patients with irreversible pulpitis. *Journal of Endodontics*. 2009; **35**: 925-9.
10. Akinosi JO. A new approach to the mandibular nerve block. *British Journal of Oral Surgery*. 1977; **15**: 83-7.
11. McMinn R.M.H (2005) Lasts anatomy regional and applied. (9th edn), Churchill Livingstone, p634.
12. Steinkruger G, Nusstein J, Reader A, Beck M, Weaver J. The significance of needle bevel orientation in achieving a successful inferior alveolar nerve block. *Journal of the American Dental Association*. 2006; **137**: 1685-91.
13. Matas R. The story of the discovery of dental anesthesia by nerve blocking: achievements of William Steward Halsted. *Surgery*. 1952; **32**: 530-7.
14. Malamed SF (2001) Handbook of local anesthesia. (4th edn) St. Louis, Mosby, p.193-219.
15. Madan GA, Madan SG, Madan AD. Failure of inferior alveolar nerve block: exploring the alternatives. *Journal of the American Dental Association*. 2002; **133**: 843-6.
16. Gow-Gates G, Watson JE. Gow-Gates mandibular block: applied anatomy and histology. *Anesthesia Progress*. 1989; **36**: 193-5.
17. Jacobs S, Haas DA, Meechan JG, May S. Injection pain: comparison of three mandibular block techniques and modulation by nitrous oxide:oxygen. *Journal of the American Dental Association*. 2003; **134**: 869-76.
18. Todorovic L, Stajcic Z, Petrovic V. Mandibular versus inferior dental anesthesia: clinical assessment of 3 different techniques. *International Journal of Oral and Maxillofacial Surgery*. 1986; **15**: 733-8.
19. Gaum LI, Moon AC. The "ART" mandibular nerve block: a new approach to accomplishing regional anesthesia involving the inferior alveolar nerve (V3). *Journal (Canadian Dental Association)*. 1997; **63**: 454-9.
20. Norris L. Eye complications following Gow-Gates block technique. *Dental Anaesthesia and Sedation*. 1982; **11**: 59-60.
21. Fish LR, McIntire DN, Johnson L. Temporary paralysis of cranial nerves III, IV, and VI after Gow-Gates injection. *Journal of the American Dental Association*. 1989; **119**: 127-30.