

A Treatment Approach for a Young Patient with Severe Amelogenesis Imperfecta

Kenan Cantekin, Huseyin Simsek, Ibrahim Sevki Buyukbayrakdar

Department of Pediatric Dentistry, Faculty of Dentistry, Erciyes University, Kayseri, Turkey

Abstract

Amelogenesis imperfecta (AI) is a hereditary disorder that affects the dental enamel on primary and permanent teeth. It is a rare disease, but it requires a difficult dental treatment particularly in severe cases. A 13-year-old girl with AI presented with an unaesthetic appearance, hypersensitivity, decreased vertical dimension and psychological problems. The patient was diagnosed as having a hypoplastic form of AI for both her permanent and primary dentition. First, the primary teeth were extracted, and then a stainless steel crown was used to reduce the dental sensitivity and increase the vertical dimension in the molar teeth. Strip crowns were also used to improve the patient's appearance in the anterior region. Finally, direct composite restorations were performed manually on the premolar teeth. Follow-up examinations were carried out at the end of the 3rd, 6th, 12th, and 24th months. The recall examination at the 24th month revealed no pathology.

Key Words: Amelogenesis imperfect, Dental treatment, Pediatric

Introduction

Amelogenesis imperfecta (AI), which was first identified in 1890, is a disease that affects the structure of the enamel in both primary and permanent teeth [1]. It was initially identified as hereditary brown tooth enamel; then, Finn [2] named it the brunette hypoplasia. Epidemiological studies found the incidence of AI to be 1:14,000 and 1:15,000 [3,4]. There are several classifications for AI, but the classification made by Witkop is the most commonly used [5-8]. This classification divides AI into four main groups: hypoplastic, hypocalcified, hypomature, and hypoplastic or hypomature with taurodontism. These four groups are determined by the clinical, histological, radiological, and genetic properties [8,9]. Patients who have the different AI sub-groups nevertheless share similar symptoms such as tooth sensitivity, an unaesthetic appearance, and lack of function [4].

The most common form of AI is the hypoplastic type in which the structure of the enamel is normal, but the thickness is reduced. The enamel does not reach normal thickness during its development. Pits and fissures are also observed on the bright yellow hard surface of the enamel. Crowns can be cylindrical or conical. In addition, there is generally no contact between the teeth. Although all the structures of these teeth can be observed radiologically, the teeth are either very thin or not there at all. Therefore, teeth with AI look like prepared teeth [10,11].

A multidisciplinary, long-term dental approach is mandatory in treating AI, to resolve the unaesthetic appearance and the functional problems caused by the insufficient crown size in the permanent dentition and the loss of vertical dimension associated with the insufficient crown size [12]. However, treatment of this disease is not only very important for overcoming the problems of appearance and function, but also to help to ensure that the patient's socio-psychological state is affected positively. The treatment for AI is varied and depends on the severity of the disease as well as the patient's general oral status, age, and socio-economic status.

In our case report, the patient, who had hypoplastic type AI according to the Witkop classification, was evaluated in accordance with the etiological factors and was operated on with periodontal and restorative treatments. The patient's functional, psychological, and aesthetic discomfort was resolved, and these discomforts have been discussed in accordance with the existing literature.

Case Report

A 13-year-old female patient had been referred to the Department of Paediatric Dentistry, at Atatürk University, Turkey, with her main complaint being poor aesthetics with open bite in the anterior region and severe dentin hypersensitivity in the posterior region. When the patient came to our department, she was unhappy and withdrawn because of her teeth. When she spoke, she covered her teeth as much as she could. Her parents said that her relationships with friends were not good because of her teeth and her appearance. The patient has five sisters, and no similar situation had been noted in her family history. AI had not been found in her father, her mother, her grandfather, or her grandmother. The parents did not have a consanguineous marriage. However, the patient had mild cerebral palsy (hypoxia) during the birth, and her periodontal health and oral hygiene were not good. All the patient's teeth were affected by AI and had yellow-brown stains on them. Her teeth were all quite small and there were diastemas between the teeth. Because her premolar teeth had not erupted, 65 and 85 of the patient's primary teeth were still present. Although caries was not seen on the anterior teeth, attrition and coloration were found. The dentin was exposed due to attrition of the molars. As a result, the exposed dentin was hypersensitive. Vertical dimension was reduced because of the attrition, and the facial height was determined by lower. No pathological condition was seen on the orthopantomograph and intraoral periapical radiographs (*Figure 1a*). The enamel layer was very thin, and the radio-density of the enamel was determined to be normal. The upper canines and the lower right canine were found to be impacted because of ectopic eruptions. In addition, the third molars were not available, which was found to be congenital

(Figures 1b-d). After the clinical and radiographic examination, the patient was diagnosed with hypoplastic AI.

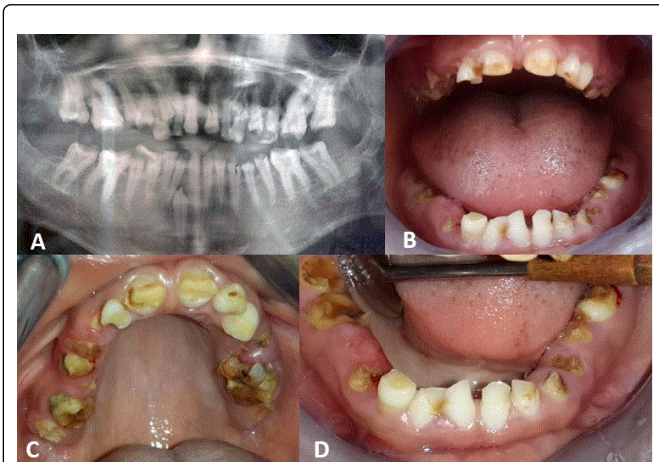


Figure 1: (a) OPT view of the patient showing radiographic features. (b) Frontal view of the maxillary and mandibular arch before the treatment. (c) Occlusal view of the upper arch before the treatment. (d) Occlusal view of the lower arch before the treatment.

The initial treatment involved extracting the exfoliative primary teeth. After the 1st week, when the extraction areas had recovered fully, the patient received periodontal treatment, followed by oral hygiene training during the 2nd week. The patient was then ready for the restorative treatment. Treatment planning was done according to the patient's age, the current condition of her teeth, and her aesthetic and functional needs. The stainless steel crown (3M ESPET™ Stainless Steel Primary Molar Crowns, Seefeld, Germany) was made after the existing dental caries had been removed, and minimal preparation was undertaken. The smallest of the stainless steel crowns that are produced for primary teeth was consistent with the patient's teeth because they were very small. Then, a composite strip crown (3M™ Pediatric Anterior Transparent Strip Crowns, Seefeld, Germany) was made on the anterior teeth to eliminate the aesthetic problems. The crown required little preparation because it was short. The bond (Futurabond U, VOCO, Cuxhafen, Germany) was applied after 37% phosphoric acid etch (Vococid, VOCO, Cuxhafen, Germany) had been performed. Composite was placed, then excess composite was removed, and the cure was achieved from all directions. Direct composite restorations were undertaken to close the diastema on the anterior teeth that had formed after the application of the strip crown (Figure 2a-c). Also, anterior open bite was reduced with composite restorations. Treatment was suspended for six months, to evaluate the success of the restoration and the patient's adaptation to the new vertical dimension before the treatment of the premolars. No problems were encountered during this time. In the treatment of the premolar teeth, the length of the clinical crown was extended with gingivectomy by using a diode laser (Doctor Smile Simplifier, Lambda S.p.A., Brendola, Italy) for the retention of the restoration, because the crowns of the teeth were short, irregular and enlarged around the gums. The patient's recovery lasted for 2 weeks. A polycarbonate crown was considered for the treatment of the premolar teeth; however, a compatible polycarbonate crown

could not be found because of the very small size of the patient's teeth. Therefore, direct composite restorations were made on the premolar teeth. Restorative compliance with soft tissue was considered to be good in the two year control visits (Figure 2d). But fractures were observed on 21 and 15 of the patient's composite restorations and these were retreated with composite. The patient has been suggested that full mouth rehabilitation with ceramic restoration can be done in the future.

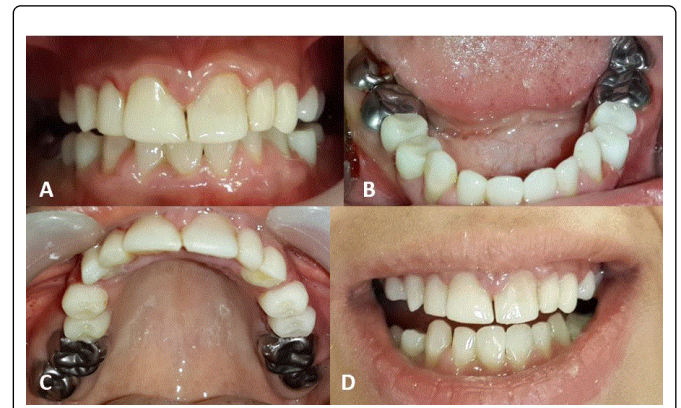


Figure 2: (a) Clinical view showing post-treatment. (b) Occlusal view of the lower arch after the treatment. (c) Occlusal view of the upper arch after the treatment. (d) Follow-up after 24th months.

Discussion

There is usually a family history in patients with AI, so parents of children who develop this disease know what their child is likely to encounter it in the future [13,14]. However, our patient had no family history of AI, and the parents thought that the existing problems would improve in time. Therefore, the application period for a comprehensive treatment was extended. Developing teeth are sensitive to neurological systemic factors [15]. Herman and Mcdonald conclude that the prevalence of enamel hypoplasia in children with cerebral palsy is considerably higher than in healthy children [16]. Mild cerebral palsy was seen in our patient, and AI is thought to be linked to this neurological disturbance. Diagnosis is important for patients with AI because this is what determines the type of the treatment they should receive. It has been reported that, while hypocalcified types of AI can be restored with crowns and prosthodontic treatment methods, hypoplastic types of AI can be restored with composite resins [17]. In previous studies, patients with hypoplastic types of AI were treated with various applications such as porcelain fixed crowns, composite restorations, stainless steel crowns, laminate, onlays, and overdentures [18]. In our patient, after considering her age, strip crown and composite resin were chosen for treating the anterior teeth to ensure her aesthetic requirements. Gingivectomy was applied at the premolar teeth to obtain a healthy gum tissue around the teeth and to increase the retention of the restoration to these teeth. Temporary crowns or stainless steel crown can be used in patient with vertical dimension loss to ensure the occlusion [12]. In our case, a stainless steel crown was made to treat the decreased vertical dimension and to provide the function of the posterior teeth. The age of the patient is an important criterion for the decision regarding stainless steel crowns. Composites are

preferable in complex cases because of the development properties and application methods that are available [19]. The biocompatibility of the composites in soft tissues was seen as good in the studies [20]. Therefore, direct composite restorations were selected for the premolar teeth in the present case. But microleakage, fracture and staining problems within composite may occur in the long term. We observed two composite restoration fracture in 2-year control visit. So that, patient was informed that full coverage crown can be done in the future.

It is also very important to prevent any psychological problems that might be caused by AI [21]. When the patient came to our clinic, she was unhappy, surly, and spoke very little. After the treatment, she became friendly and chatty, which was quite striking.

In summary, treatment for the lack of function, the phonetics and the aesthetic problems in patients with AI is a necessity that has been proposed by many researchers. In such patients, treatment must be started as early as possible to prevent tissue destruction and early tooth loss [22]. A 14-year-old female patient with hypoplastic AI was treated in the present case. The patient's age, socio-economic status, severity, type of AI and her intraoral situation were all important for the treatment planning. Our aim was to treat the psycho-social as well as the functional and aesthetic problems. After the treatment, no negative situation was encountered during the follow up, and the patient reports being very satisfied.

References

1. Witkop CJ Jr. Heterogeneity in inherited dental traits, gingival fibromatosis and amelogenesis imperfecta. *Southern Medical Journal*. 1971; **64**: 16-25.
2. Finn SB. Clinical pedodontics. 4th ed 1973, Philadelphia; London: Saunders.
3. Williams WP, LH Becker. Amelogenesis imperfecta: functional and esthetic restoration of a severely compromised dentition. *Quintessence International*. 2000; **31**: 397-403.
4. Seow WK. Clinical diagnosis and management strategies of amelogenesis imperfect variants. *Pediatric Dentistry*. 1993; **15**: 384-93.
5. Witkop CJ Jr, W Kuhlmann, J Sauk. Autosomal recessive pigmented hypomaturational amelogenesis imperfecta. Report of a kindred. *Oral Surgery Oral Medicine Oral Pathology*. 1973; **36**: 367-82.
6. Aldred MJ, PJ Crawford. Amelogenesis imperfecta: autosomal dominant hypomaturational-hypoplasia type with taurodontism. *Brazilian Dental Journal*. 1988; **164**: 310.
7. Crawford PJ, RD Evans, MJ Aldred. Amelogenesis imperfecta: autosomal dominant hypomaturational-hypoplasia type with taurodontism. *Brazilian Dental Journal*. 1988; **164**: 71-3.
8. Witkop CJ Jr. Amelogenesis imperfecta, dentinogenesis imperfecta and dentin dysplasia revisited: problems in classification. *Journal of Oral Pathology*. 1988; **17**: 547-53.
9. Langlais RP and CS Miller. Color atlas of common oral diseases 1992: Lea & Febiger.
10. Bouvier D, Duprez JP, Pirel C, Vincent B. Amelogenesis imperfecta--a prosthetic rehabilitation: A clinical report. *Journal of Prosthetic Dentistry*. 1999; **82**: 130-1.
11. Ayna E, S Celenk, ET Kadiroglu. Restoring function and esthetics in 2 patients with amelogenesis imperfecta: case report. *Quintessence International*. 2007; **38**: 51-3.
12. Ergun G, Kaya BM, Egilmez F, Cekic-Nagas I. Functional and esthetic rehabilitation of a patient with amelogenesis imperfecta. *Journal of Canadian Dental Association*. 2013; **79**: d38.
13. Shaw JC. Taurodont Teeth in South African Races. *Journal of Anatomy*. 1928; **62**: 476-498.
14. Kwok-Tung L, NM King. The restorative management of amelogenesis imperfecta in the mixed dentition. *The Journal of Clinical Pediatric Dentistry*. 2006; **31**: 130-5.
15. Bhat M, KB Nelson. Developmental enamel defects in primary teeth in children with cerebral palsy, mental retardation, or hearing defects: a review. *Advance Dental Research*. 1989; **3**: 132-42.
16. Alhammad NS. Tooth wear, enamel hypoplasia and traumatic dental injuries among cerebral palsy children of Riyadh city. *King Saud University Journal of Dental Sciences*. 2011; **2**: 1-5.
17. Sundell S. Hereditary amelogenesis imperfecta. I. Oral health in children. *Swedish Dental Journal*. 1986; **10**: 151-63.
18. Bouvier D, JP Duprez, D Bois. Rehabilitation of young patients with amelogenesis imperfecta: a report of two cases. *ASDC Journal of Dentistry for Children*. 1996; **63**: 443-7.
19. Furuse AY, Cunha LF, Moresca R, Paganelli G, Mondelli RF, Mondelli J. Enamel wetness effects on bond strength using different adhesive systems. *Operative Dentistry*. 2011; **36**: 274-80.
20. Furuse AY, Herkrath FJ, Franco EJ, Benetti AR, Mondelli J. Multidisciplinary management of anterior diastemata: clinical procedures. *Practical Procedures & Aesthetic Dentistry*. 2007; **19**: 185-91.
21. Lamb DJ. The treatment of amelogenesis imperfecta. *Journal of Prosthetic Dentistry*. 1976; **36**: 286-91.
22. Yip HK, RJ Smales. Oral rehabilitation of young adults with amelogenesis imperfecta. *International Journal of Prosthodontics*. 2003; **16**: 345-9.