

The cyst, the benign jaw tumor and the LitAr material

Medea Olennikova

Penza, Russia

Summary

The *object* of the investigations was to qualitatively evaluate all the possibilities of using the collagen-apatite biodegradable material for jaw defect plasty after removing the vast cysts and benign tumors including the tumors with direct and postponed replanting of teeth.

LitAr implantation material was used to fill the defect cavities - it ensures reparative osteogenesis within the shortest possible time. The material biodegradation was checked roentgenologically.

Material and method. It was possible to treat 42 patients aged 8 to 65 years old for cysts and benign tumors. Replanting of teeth was performed in some patients.

Results. There were no complications in all the cases in the postoperative time period. It was possible to observe roentgenologically the first osteogenesis signs in the defect zone, from the 14th to the 30th day after performing the operation. Within 3-6 months there was a dense bone tissue.

On the basis of the obtained results it is possible to make a conclusion that LitAr collagen-apatite biodegradable material, in case of filling jaw bone defects with it, ensures reparative osteogenesis in the shortest possible time even in case of replanting the teeth.

Keywords: osteogenesis, cyst, benign jaw tumor, LitAr material, replantation.

Introduction

At present, for the purpose of regenerating the anatomically and functionally sound bone structures of the jaws after removing the sizable cysts and the benign tumors certain diverse materials are used. They replace the bone defects and make a major contribution to restoring a sound bone tissue: auto-tissues, allotransplants, synthetic materials [1,2].

Nevertheless, all the materials to be implanted not always ensure a favourable postoperative time period.

Among the most frequent causes for complications are: operation traumas, inflammations (especially in the cystophorous cavities) and an irrational choice of plastic materials [3].

Objective

The object of the investigations was to qualitatively evaluate all the possibilities of using the collagen-apatite biodegradable material for jaw defect plasty after removing vast cysts and benign tumors including the tumors with direct and postponed replanting of teeth.

The basic criteria for choosing the materials to be implanted in replacement surgery are: biocompatibility, immunologic inertia, rapid vascularization in the implantation zone.

Material and method

The most promising materials for the application are synthetic, biodegradable implants, made on the basis of a polymeric

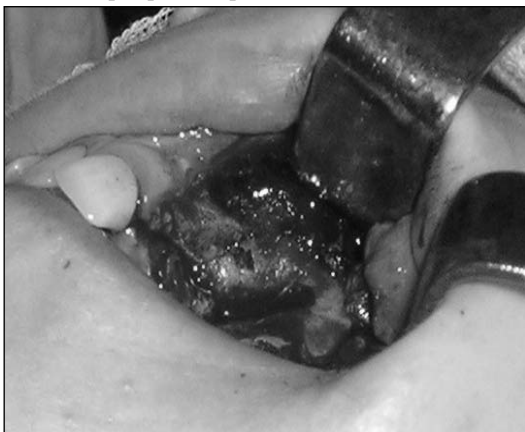
organic matrix and hydroxyapatite ensuring a reparative osteogenesis [4,5,6].

One of these materials is the LitAr collagen-apatite composite – it ensures reparative osteogenesis within the shortest possible time [2]. The collagen-apatite implant LitAr was made by directed ion diffusion of Ca^{2+} , PO_4^{3-} , OH^- in bulk of collagen with the result that a material was formed, with a content of 40-70% (weight) of hydroxyapatite (depending on the implant producing conditions). The obtained material was checked by X-ray phase analysis, infrared spectroscopy, thermal differential analysis, computed tomography, and morphologically. We performed a chemical analysis for content of Ca^{2+} (complexometrically) and of PO_4^{3-} (lanthanometrically, spectrophotometrically). The material was sterilized by gamma radiation (25 kGr) before use.

The biological tests have shown that the LitAr implant corresponds to the essential requirements, which can be placed upon the implantation materials inducing reparative osteogenesis.

The following methods of testing and investigating were used to check the LitAr transformation: clinical, laboratory, roentgenological, bacteriological tests and histomorphological investigations.

Figure 1. Patient S., 4.5 months later after removing the cementifying fibroma of the upper jaw, teeth 22, 23 and after filling the residual bone cavity with LitAr material. The preparation of the bed in the new-formed bone for a postponed replantation of teeth 22, 23



Results

It was possible for us to treat 42 patients ranging in age from 8 to 65 years with the LitAr material: upper jaw cysts – 7 patients, low jaw cysts – 28 patients (including 6 patients with an immediate replantation of the sources of accessional teeth); benign tumors of the upper jaw – 7 patients (a postponed replantation of teeth was performed in 4 patients).

All the operations have been performed through an intramouth access with general and local anesthesia differentiatedly according to the scope and duration of the intervention. The porous collagen-apatite LitAr material was introduced into the bone defect zone (cavity) after removing the cyst or the benign tumor and after performing a medicinal treatment. The LitAr material was introduced by 70 volume percent and the stitches were put in this wound firmly.

With a postponed replanting of teeth after 4-6 months after removing a benign tumor and extracting the teeth and after filling the defect with the LitAr material by the help of a cutter, we performed a number of saw cuts-grooves in the new formed bone structure (*Figure 1*).

The teeth were extracted from a preservation tank and then replanted into a prepared bed, the LitAr material was placed on the bone again (*Figure 2*), and the stitches were put in

Figure 2. The operation stage: teeth 22, 23 are replanted into a prepared bone bed; the tooth roots are covered with the LitAr material.

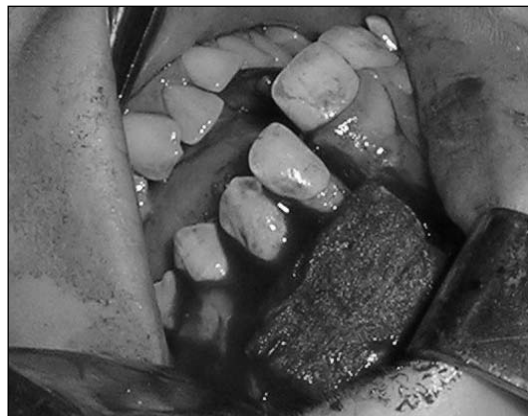

Figure 3. The operation stage: the wound is sutured

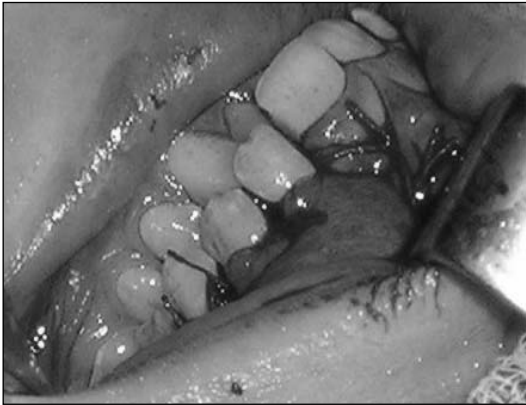

Figure 4. The roentgenogram of Patient S. by the 10th day after performing the operation

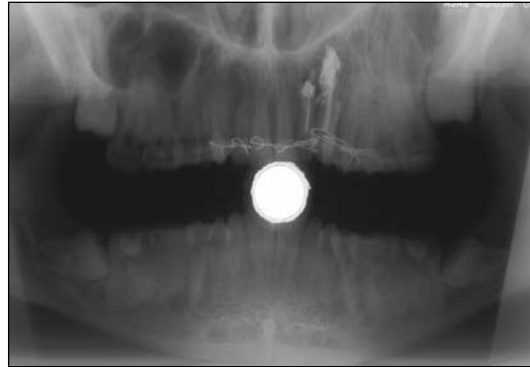

Figure 5. The roentgenogram of Patient S., 2 months after performing the operation

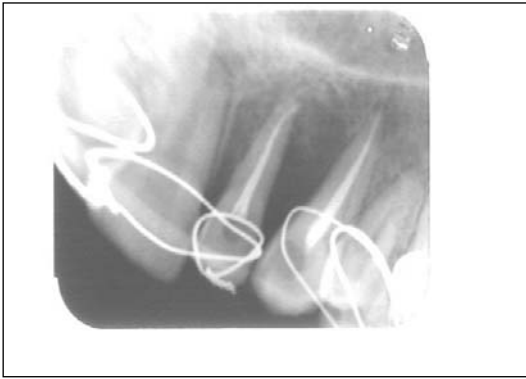

Figure 6. The roentgenogram of Patient S., 1 year after performing the operation

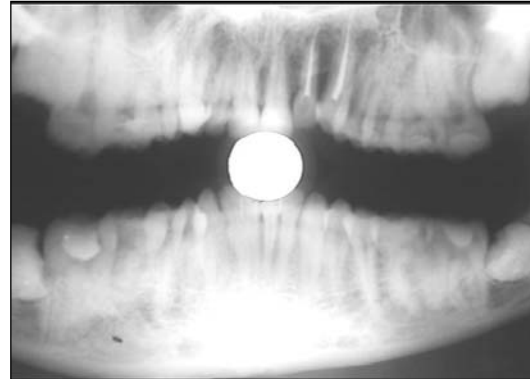
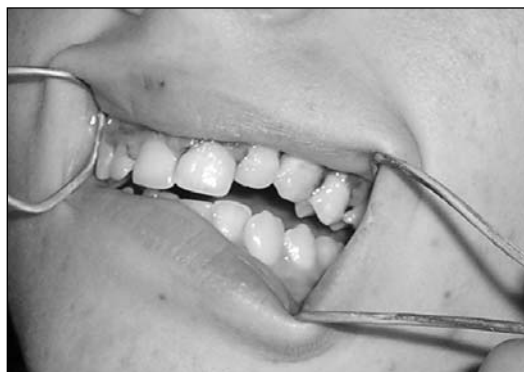

Figure 7. The state of the replanted teeth of Patient S., 1 year after performing the operation



the wound (*Figure 3*). The fixation of the already implanted teeth was performed with the help of a smooth clamp for a time period of 1.5 or 2 months.

The medicinal therapy consisted of anti-bacterial preparations, the immunomodulator “Cyclopheron”. There were no complications in all cases in the postoperative time period.

We stated a moderate swelling of the surrounding tissues, which was treated every two or four days. Dynamics of the reconstructed bone structure in the defect zone within 10 days (*Figure 4*), within 2 months (*Figure 5*) and within 1 year (*Figures 6*) was traced roentgenographically.

The density magnification of the X-ray picture occurred from the periphery to the center of the bone defect from the 14th day to the 30th day. Everything became homogeneous by the 60th day. In relation to the defect bulk, forming of the bone structure took place over a period of 3-6 months.

References

1. Eick JD, Bear L, Cobb CM et al. Mechanical behaviour of mandibular continuity defects reconstructed using combinations of hydroxyapatite and autogenous bone. *J Oral Maxillofac Surg.*, 1990; 48(8): 823-830.
2. Леонтьев ВК, Литвинов СД, Судакова ТВ. Имплантационные материалы для замещения дефектов костной и хрящевой ткани. *Российский вестник дентальной имплантологии*, 2003; 2: 10-19.
3. Lapshin SD. Experience in using hydroxyapatite in operative dentistry practice. *Stomatologiya (Mosk).*, 1999; 2: 59-61.

Conclusion

Thus, the LitAr collagen-apatite biodegradable material ensured restoring the bone structure in the zone of enormous jaw defects after removing cysts and benign neoplasms. On the basis of the obtained results it is possible to conclude that the LitAr collagen-apatite biodegradable material, in the case it is used to fill jaw bone defects, ensures reparative osteogenesis in the shortest possible time even in the case of replanting (direct and postponed) of teeth.

4. Gregori M, Orly J, Menantean J. The influence of calcium phosphate biomaterials on human bone cell activities. An in vitro approach. *J Biomed Mater Res*, 1990; 24(2): 165-172.
5. Ducheyne P, Beight J, Cuskler J et al. Effect of calcium phosphate coating characteristics on early post-operative bone tissue ingrowth. *Biomaterials*, 1990; 11(8): 531-540.
6. Litvinov SD, Rakhimov RL, Efremov AY. Treating odontogenic childrens cysts with the use of the material LitAr. *Int. Dent. J.*, 2001; 5: 377.

Correspondence to: Dr. Medea Olennikova, Candidate of Medical Sciences; 18, Lermontova str., Regional Clinical Hospital after N.N. Burdenko, Penza, Russia. E-mail: LSD@samtel.ru