

Analysis of the condyle/fossa relationship in Kennedy class I and II partially edentulous subjects*

Nuran Yanikoglu¹, M. Ustun Guldag²

¹ Erzurum, ² Isparta, Turkey

* Presented at the 25th Annual Conference of the European Prosthodontic Association, Prague, Czech Republic, 6-8 September 2001

Summary

The purpose of this study was to radiographically identify the condylar position in the glenoid fossa in Kennedy class I and II patients.

Sixty patients diagnosed as Kennedy Class I or II were investigated in this study. Half of these patients had existing removable partial dentures (RPD) whereas thirty patients with class I occlusion and without any restorations were assessed as control. Temporomandibular Joint (TMJ) radiographies of the patients were taken utilizing a panoramic x-ray unit program. Anterior, superior and posterior joint spaces between glenoid fossa and condyle in both the right and left TMJs were measured. Data were analyzed using ANOVA.

A statistically significant difference was found between the patients with and without dentures in the position of right and left condyles ($P<0.001$). In class I patients, significant statistical differences were found between right and left TMJs in both the X axis values ($P<0.001$) and the Y axis values ($P<0.05$). The difference between the right and the left X axis values in Kennedy class II patients was also statistically significant ($P<0.001$).

The average values of the posterior, anterior and superior joint spaces and the distance between the two centers on the axis were found to be higher in Kennedy class II than those in Kennedy class I patients.

Keywords: mandibular condyle position, TMJ radiograph, partially edentulous patients.

Introduction

Edentulous mandibles undergo several dimensional changes related to age and dentition and/or nearly complete or complete loss of dentition [1-3]. Moffett et al. [4] noted remodeling of all TMJs at necropsy of 30 subjects of various ages. This remodeling was thought to be related to occlusal alterations. Such occlusal alterations in centric occlusion (due to loss of teeth and abrasion) can lead to pathologic displacement of the

condyle, including posterior displacement [5].

The TMJ space has been defined as the radiographic lucency between the osseous portions of the condyle and the articular eminence and fossa. TMJ space may change in width through normal or abnormal function due to such factors as mandibular posturing, altered thickness of the articular soft tissues separating the osseous joint components and degenerative and remodeling changes in morphology of the osseous components of the TMJ [6].

¹ Professor, Department of Prosthodontics, School of Dentistry, Atatürk University, Erzurum, Turkey

² Professor, Department of Prosthodontics, School of Dentistry, Süleyman Demirel University, Isparta, Turkey

Utilizing transcranial radiography on patients with TMJ dysfunction syndrome, Weinberg [7] concluded that occlusion should be established when the condyles are symmetrically positioned in their fossae with equal anterior and posterior joint spaces. Through joint space analysis, the condyle-fossa relationship has been examined by numerous imaging and analysis techniques [8-13]. Conventional techniques used to aid such analysis include transcranial radiographs, pantomography, transpharyngeal view and transorbital view. These techniques still provide information that may not be apparent in advanced imaging modalities [14].

Brewka [15] suggested, however, that pantographic hinge axis (center of the condyle) location is more precise than use of the cephalometric center of the condyle as the hinge axis. Richard and Gwner [13] observed that the most reliable information about the anterior-medial zone was obtained from orthopantomograms. When required, more sophisticated imaging methods such as tomography, computed tomography, arthrography and magnetic resonance imaging may be utilized [14]. TMJ radiographs, obtained in the acquired centric occlusion, reveal the condyles to be slightly retruded in both fossae [16]. Ismail and Rokni [11] indicated that when centric relation was compared to centric occlusion, the condyles were positioned more posteriorly and superiorly in centric relation position.

None of the radiographic techniques described above were found to be superior in their ability to accurately depict the dimensions of the joint space [17]. The relationship between the condyle and the glenoid fossa of the temporomandibular joint has previously been studied with natural teeth in place. This same relationship has rarely been studied in edentulous patients [18] and the positional relationship of the condyle to the glenoid fossa has not yet been investigated in partially edentulous patients

utilizing the Kennedy classification.

The purpose of this study was to identify radiographically the condylar position in the glenoid fossa in Kennedy class I and class II partially edentulous patients.

Materials and method

A total of 60 patients divided into two groups were evaluated in this study. In the first group, 30 unilaterally and posteriorly partially edentulous patients (21 women and 9 men with an age range of 32 to 56 years) were studied (Kennedy II); within this group, patients had been wearing removable dentures for between 2 and 15 years.

The second group consisted of 18 women and 12 men with an age range of 30 to 62 years who were bilaterally and posteriorly partially edentulous, except first premolar teeth (Kennedy I). Within the first group, there were 6 men and 14 women with an existing denture while, 9 men and 11 women with an existing denture were in the second group of patients.

Participating patients had class I occlusion and edentulous patients had no restorations such as fixed or removable partial dentures or other conservative treatments. The control group consisted of 30 patients (18 women and 12 men) with class I occlusion and without restorations and with an age range of 21 to 38 years.

A PM 2002 CC Proline Panoramic x-ray unit was used to take all radiographs in this study using Kodak T-Mat G film and Lanex regular screens. Both open and closed views of the left and right TMJs are obtained at the same time as temporomandibular joint exposures.

The patient's head was positioned so that the Frankfort Plane would tilt down 5°. The back of the patient's head was supported by the operator's hand, using the Frankfort Plane light as a reference line, adjusting the position of the patient's head by raising or lowering the vertical carriage

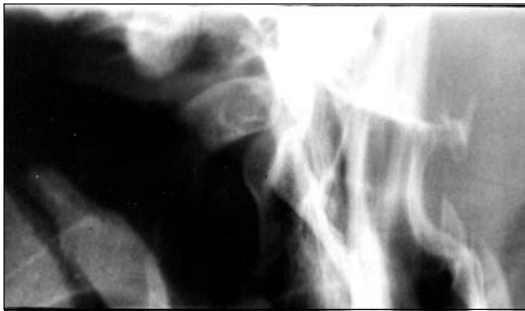with the height adjusting keys.

All radiographs used in this study were taken with the same Panelipse machine by the same individual (Figure 1). The radiographs of all groups were taken in centric occlusion. In centric occlusion position, both condyles were symmetrically positioned in their fossae with equal spatial distances anteriorly and posteriorly.

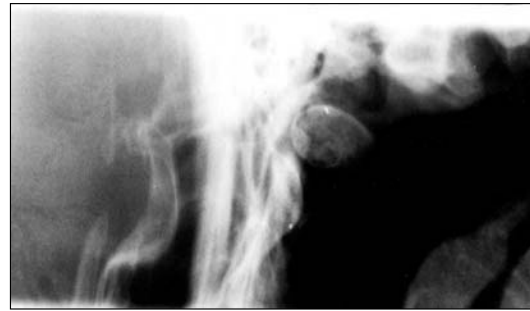The condyle and the glenoid fossa on the radiographs were traced on acetate paper. A reference line was drawn parallel to the Frankfort horizontal plane and tangent to the most superior aspect of the glenoid

fossa. Line A was drawn perpendicular to the reference line through the highest point of the glenoid fossa. Line B was then drawn at a 45-degree angle to the reference line across the thinnest part of the anterior joint space. Line C was also drawn at 45-degree to the reference line passing through lines A and B and also passed through the posterior joint space. The length of lines (A, B, and C) between the condyle and the glenoid fossa represented the width of the superior, anterior and posterior joint spaces, respectively (Figure 2).

Figure 1. Condylar head in TMJ

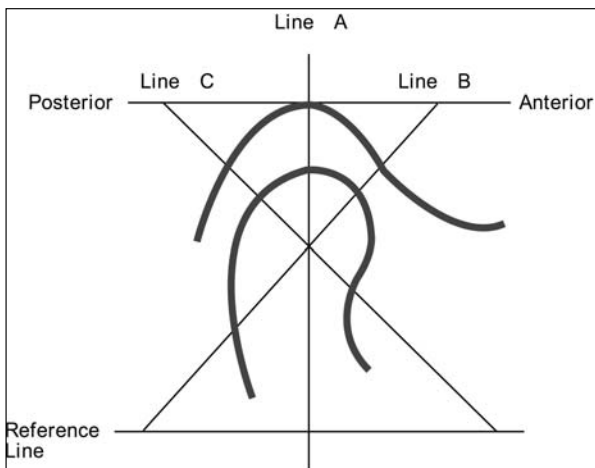


A. Right



B Left

Figure 2. Location of anterior, superior, and posterior joint spaces.[16]



The centers of the condyle and the glenoid fossa were located as suggested by Brewka [15] utilizing an X, Y coordinate system. In order to determine the center of

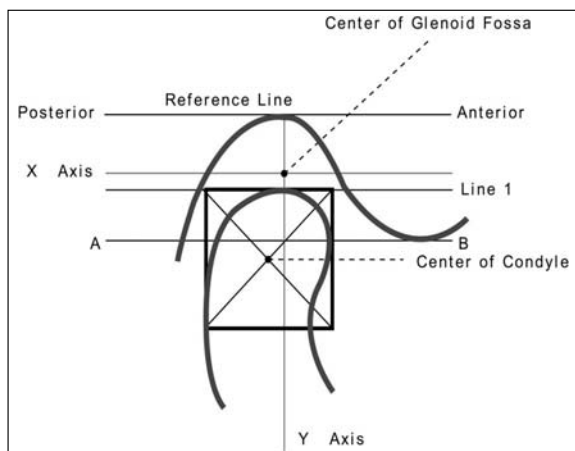
the condyle, a line was drawn on the tracing parallel to the top edge of the film tangent to the most superior aspect of the glenoid fossa. This line was parallel to the Frankfort horizontal plane because of the positioning of the patient's head in the head-holder and was used as the reference line.

A line parallel to the reference line was drawn tangent to the highest point of the condyle (line 1). Two lines perpendicular to line 1 were drawn tangent to the most anterior (line 2) and most posterior (line 3) aspect of the head of the condyle. The distance between lines 2 and 3 was measured and recorded. Line 4 was drawn parallel to line 1 and at a distance equal to the distance between lines 2 and 3. Diagonal lines were drawn in the square formed by these lines. The intersection of the diagonals represented the center of the condyle.

To determine the center of the glenoid fossa, Line A-B was drawn tangent to the crest of the articular eminence and parallel to the reference line. Another parallel line was drawn midway between line A-B and the reference line representing the X axis. The Y axis was drawn perpendicular to the reference line, at the point where the reference line intersected the height of the fossa. The point of intersection of the X and Y axis (the 0 point) indicates the center of the glenoid fossa. The distance from the center of the condyle to the center of the glenoid fossa on the X axis and Y axis was measured and recorded (*Figure 3*).

All data were analyzed utilizing one-way analysis of variance (ANOVA) and LSD (Least square differences) test.

Figure 3. Location of centers of condyle and glenoid fossa.[16]



Results

Results of ANOVA analysis on the left side radiographs showed that with and without an existing removable partial denture, the Kennedy classifications were significant factors at $P < 0.01$ and $P < 0.05$ level, respectively, in terms of the X axis values. On the right side however, age and time periods

were significant at $P < 0.05$ level for X values whereas sex was significant at $P < 0.05$ level for the Y axis value and superior joint distance. An existing denture was found to be a significant factor in posterior TMJ distance at $P < 0.01$ level.

Kennedy class I: Analysis of the variance showed the mean values of distance from the center of the condyle to the center of the glenoid fossa were $X = -1.33$ mm, $Y = -7.37$ mm on the left side and $X = 1.64$ mm, $Y = -8.00$ mm on the right side. The mean left joint spatial measurements were 5.46 mm superiorly, 2.52 mm anteriorly, and 3.54 mm posteriorly, while the mean measurements for the right side were 5.85 mm, 2.39 mm and 3.98 mm, respectively. The differences between the X and Y axis were statistically significant at $P < 0.001$ and $P < 0.05$, respectively. However, the superior, anterior and posterior distance differences of glenoid fossae were not statistically significant.

Kennedy class II: The mean values of distance between the two centers on the X and Y axis were $X = -2.06$ mm and $Y = -6.96$ mm for the left side, however, these mean values were $X = 1.45$ mm and $Y = -7.55$ mm for the right side. The mean left joint measurements in Kennedy class II patients were 5.54 mm superiorly, 2.57 mm anteriorly, and 4.02 mm posteriorly, whereas the mean measurements for the right side were 5.85 mm, 2.14 mm and 3.90 mm, respectively. A group comparison test was carried out in order to better understand the effect of a dentulous right or left side on the TMJ measurements, revealing statistically significant results. The differences between the left and right sides were analyzed by LSD test, and this analysis showed that the X axis value differences were statistically significant at $P < 0.001$ level.

Control group (dentulous patients):

The mean values of distance between the two centers on the X and Y axis were $X = -2.48$ mm and $Y = -3.91$ mm for the left side, and $X = 2.60$ mm, $Y = -4.05$ mm for the right

side. Mean left joint measurements in the dentulous patients were 5.00 mm superiorly, 3.10 mm anteriorly and 4.10 mm posteriorly while these measurements were 4.71 mm, 2.85 mm and 4.08 mm for the right side, respectively. LSD analysis revealed no statistical difference between the respective X and Y coordinate values in these patients.

Discussion

Hatjigiorgis et al [8] examined the positional relationship between the condyle and glenoid fossa tomographically on dentulous and edentulous patients. A great variability of condylar positions within the glenoid fossa in centric relation at the vertical dimension of occlusion and remodeling was observed primarily on the condyle. In their radiographic study carried out on edentulous patients, Hongchen et al. [6] examined the positional changes of the condyle in the glenoid fossa and the changes in the superior, anterior and posterior joint spaces. Their results demonstrated that the condyle has the potential to move significantly backwards and upwards.

In the present study, the condylar position in TMJs was examined in unilaterally edentulous patients (Kennedy II) and bilaterally edentulous patients (Kennedy I) with and without dentures. When data were analyzed utilizing ANOVA, we found that there were significant statistical differences between the right and left TMJs in both the X axis values and the Y axis values. Differences in X axis values between the right and left sides in Kennedy class II patients were also found to be statistically significant.

Mongini [1] suggested that unilateral condylar displacement was not significantly related to age or the number of missing teeth. Characteristic alterations in the shape of the condyles may be brought about as the result of condylar displacement in centric occlusion. Symmetrical posterior displace-

ment appears to occur more frequently in older subjects with fewer teeth. The absence of the support of posterior teeth can also lead to posterior or superior condylar displacement. Superior condylar position is influenced by the posterior teeth and meniscus. The teeth, muscles and disc support and guide the condyle in its suspension within the fossa [16].

When the vertical dimension was lost, the condylar position within the glenoid fossa may change. Since this changed condylar position may be pathological, it may be referred to as the edentulous position of the TMJ. In this position, the upper and posterior joint spaces are obviously reduced [11].

The mandible may move forward and upward as abrasion of the natural teeth or artificial teeth occurs [18]. If an edentulous patient does not have a complete denture for a long time, the condyle moves towards a more backwards and upwards position [11]. The distance from the center of the condyle to the center of the glenoid fossa on the Y axis will then decrease. When a denture is made for such a patient, the position of the condyle in the glenoid fossa and the relationship of the maxilla and mandible should be improved [18]. Studies have shown that the position of the glenoid fossa was more anterior in edentulous subjects than in dentulous patients [19].

In the present study, the mean condylar position for dentulous patients was slightly forward and upward as compared with the partially edentulous group. In their study on tomographies clinically obtained from the individuals and human cadaver anatomically, Mongini et al. [1] examined the relationship between the loss of teeth and changes in TMJ. Results of that study showed that extensive remodeling of the TMJ takes place throughout adult life, and can lead to marked changes in the shape of that joint. The degrees of remodeling and the new shape imposed on the condyles are closely

related to changes in the dentition.

Changes in the mandible, such as alveolar bone height and size of the gonial angle related to the duration of the edentulousness, have been studied earlier but there is no data available in the literature comparing bicondylar asymmetry and the position of the mandible and the glenoid fossa in relation to the cranium in edentulous versus dentulous subjects. In the absence of a complete segment of teeth, such as the lower posteriors, the mandible may be pulled upward in the distal area because of a lack of a contact stop [20]. Engstrom et al. [20] stated that the gonial angle has been noted to be significantly greater in both male and female edentulous subjects than in either sex with all their teeth. Yet Ceylan et al. [21] published results concluding that there were no significant differences between the mandibular angles when comparing partially and totally edentulous subjects.

For optimum mechanical action, the gliding surfaces of the teeth should be coordinated to the gliding movements of the temporomandibular joints. [1] Restorations in Kennedy class I and II patients may be planned accordingly to replace the required teeth at the proper level and should include the proper occlusal contact on natural teeth.

The loads that act on the TMJ may be influenced by several anatomic and physical factors that have already been discussed in the literature. The most important factors seem to be the position of the occlusal contacts [22,23] and the inclinations of the occlusal and temporal articular planes [24]. Modifications of the asymmetry index changes the relative load between the two joints, and a higher temporal muscle activity increases the joint load on both the working and balancing sides [25]. The present study shows that the mean values of distance from the center of the condyle to the center of the glenoid fossa on the X axis in the dentulous side (Kennedy class II) are statistically significant $P < 0.001$.

Hekneby [22] and Koriotoh and Hannam [26] reported morphologic alterations in the TMJs of patients with altered occlusal conditions i.e., unilateral lost molars and concluded that these alterations were due to the differing loads between working- and balancing- side joints. The reaction forces that act on the TMJ during unilateral clench do not always load the balancing-side joint more than the working-side joint [26,27].

The influence of condylar position and the loss of posterior teeth on temporomandibular disorders remains a controversial issue, as does the influence of lost molar replacement by a removable partial denture [28,29]. Nevertheless, some researchers have shown the importance of prosthetic rehabilitation in reducing the symptoms of temporomandibular disorders [16,19,30].

Conclusion

Within the limitations of this study, the posterior and superior joint spaces and the distance from the center of the condyle to the center of the glenoid fossa on the X axis of the left side is decreased in Kennedy Class I patients. However, in Kennedy class II patients, the distance from the center of the condyle to the center of the glenoid fossa on the Y axis of the left side, and the anterior joint space of the right side is decreased. Statistically significant differences were found between the dentulous and edentulous sides in Kennedy II class patients (without an existing partial denture) ($P < 0.05$). The mean condylar position for the dentulous patients was slightly forward and upward, as compared with partially edentulous groups (Kennedy class I and II patients). Statistically significant differences were found between partially edentulous and dentulous subjects ($P < 0.001$). The Y axis value was smaller in dentulous patients due to the upward condylar position of the fossa in dentulous patients.

References

1. Mongini F. Anatomic and clinical evaluation of the relationship between the temporomandibular joint and occlusion. *J Prosthet Dent* 1977; **38**: 539-551.
2. Tallgren A. The continuing reduction of the residual alveolar ridges incomplete denture wearers: a mixed-longitudinal study covering 25 years. *J Prosthet Dent* 1972; **27**: 120-125.
3. Enlow DH, Bianco HJ, Eklund S. The remodeling of the edentulous mandible. *J Prosthet Dent* 1976; **36**: 685-689.
4. Moffet BC, Johnson LC, McCabe JB, Askew HC. Articular remodeling in adult human temporomandibular joint. *Am J An* 1964; **115**: 119-142.
5. Weinberg LA. Correlation of temporomandibular dysfunction with radiographic findings. *J Prosthet Dent* 1972; **28**: 519-535.
6. Hatcher DC, Blom RJ, Baker CG. Temporomandibular joint spatial relationship: Osseous and soft tissues. *J Prosthet Dent* 1986; **56**: 344-353.
7. Weinberg LA. Temporomandibular dysfunction and its effect on centric relation. *J Prosthet Dent* 1973; **30**: 176.
8. Hatjigiorgis CG, Grisivis RJ, Fenster RK, Neff PA. A tomographic study of the temporomandibular joint of edentulous patients. *J Prosthet Dent* 1987; **57**: 354-358.
9. Preti G, Fava C. Lateral transcranial radiography of temporomandibular joints. Part I: Validity in skulls and patients. *J Prosthet Dent* 1988; **59**: 85-93.
10. Pullinger AG, Hollender L, Solberg WK, Petersson A. A tomographic study of mandibular condyle position in an asymptomatic population. *J Prosthet Dent* 1985; **53**: 706-713.
11. Ismail YH, Rokni A. Radiographic study of condylar position in centric relation and centric occlusion. *J Prosthet Dent* 1980; **43**: 327-330.
12. Mongini F. The importance of radiography in the diagnosis of TMJ dysfunctions. *J Prosthet Dent* 1981; **45**: 186-198.
13. Richards LC. An assessment of radiographic methods for the investigation of temporomandibular joint morphology and pathology. *Aust Dent J* 1985; **30**: 323-332.
14. Pharoah MJ. Temporomandibular joint imaging. *Dent Clin North Am* 1993; **37**: 627-643.
15. Brewka RE. Pantographic evaluation of cephalometric hinge axis. *Am J Orthod* 1981; **79**: 1-19.
16. Weinberg LA. An evaluation of occlusal factors in TMJ dysfunction-pain syndrome. *J Prosthet Dent* 1979; **41**(2): 198-208.
17. Aquilino SA, Matteson SR, Holland GA, Phillips C. Evaluation of condylar position from temporomandibular joint radiographs. *J Prosthet Dent* 1985; **53**(1): 88-97.
18. Hongchen L, Jilin Z, Ning L. Edentulous position of the temporomandibular joint. *J Prosthet Dent* 1992; **67**: 401-404.
19. Raustia AM, Prittiniemi P, Salonen MA, Pyhtinen J. Effect of edentulousness on mandibular size and condyle-fossa position. *Journal of Oral Rehabilitation* 1998; **25**(3): 174-179.
20. Engstrom C, Hollender L, Lindquist S. Jaw morphology in edentulous individuals: a radiographic cephalometric study. *Journal of Oral Rehabilitation* 1985; **12**: 451-454.
21. Ceylan G, Yanikoglu N, Yilmaz AB, Ceylan Y. Change in mandibular angle in the dentulous and edentulous states. *J Prosthet Dent* 1998; **80**: 680-684.
22. Hekneby M. The load of the temporomandibular joint: Physical calculations and analyses. *J Prosthet Dent* 1974; **31**: 303-312.
23. Ito T, Gibbs CH, Marguelles-Bonnet R et al. Loading on the temporomandibular joints with five occlusal conditions. *J Prosthet Dent* 1986; **56**: 478-484.
24. Ferrario VF, Sforza C. Biomechanical model of the human mandible: a hypothesis involving stabilizing activity of the superior belly of lateral pterygoid muscle. *J Prosthet Dent* 1992; **68**: 829-835.
25. Ferrario VF, Sforza C. Biomechanical model of the human mandible in unilateral clench: Distribution of temporomandibular joint reaction forces between working and balancing sides. *J Prosthet Dent* 1994; **72**: 169-176.
26. Koriath TW, Hannam AG. Effect of bilateral asymmetric tooth clenching on load distribution at the mandibular condyles. *J Prosthet Dent* 1990; **64**: 62-73.
27. Faulkner MG, Hatcher DC, Hay A. A three-dimensional investigation of temporomandibular joint loading. *J Biomech* 1987; **20**: 997-1002.
28. Kayser AF. Shortened dental arches and oral function. *J Oral Rehabil* 1981; **8**: 457-462.
29. Witter DJ, Van Elteren P, Kayser AF, Van Rossum MJ. The effect of removable partial dentures on the oral function is shortened dental arches. *J Oral Rehabil* 1989; **16**: 27-33.
30. Barghi N, Dos Santos J Jr, Narendran S. Effects of posterior teeth replacement on temporomandibular joint sounds: a preliminary report. *J Prosthet Dent* 1992; **68**: 132-136.

Correspondence to: Professor Nuran Yanikoglu, DDS, PhD, Department of Prosthodontics, School of Dentistry, Atatürk University, 25270 Erzurum-Turkey. E-mail: ndinckal@atauni.edu.tr