

## Study on the dental transposition

Constantina Roman, Mihaela Anisie, Elena Damasar

Constanța, România

### Summary

**Tooth transposition presents a major challenge in the correction of a malocclusion. Its treatment difficulties make this anomaly an occurrence of orthodontic interest and a source of clinical interest. This study was carried out in order to determine the frequency of dental transposition in our population and its presence within other dento-maxillary anomalies. A clinical analysis of different forms of dental transposition is presented.**

**Keywords: dental transposition, position anomaly, frequency.**

### Introduction

Dental transposition is a developmental alteration resulting in a deviation in tooth position, clinically identified as the interchange of two adjacent teeth, that alters the natural order of the dental arch [1-3]. It may involve two clinically erupted teeth; or two intraosseous adjacent teeth; or one tooth erupted and the other intraosseous.

Tooth transposition may also be looked upon as a special case of dental ectopy, but not all the ectopic teeth are transpositioned [4].

A review of the pertinent literature shows that the cause of transposition remains unclear, although early loss or retention of temporary teeth [5,6], the transposition of the analog tooth during odontogenesis, migration of a tooth away from its normal path of eruption [7,8] and heredity are the factors most often cited [1,9,10].

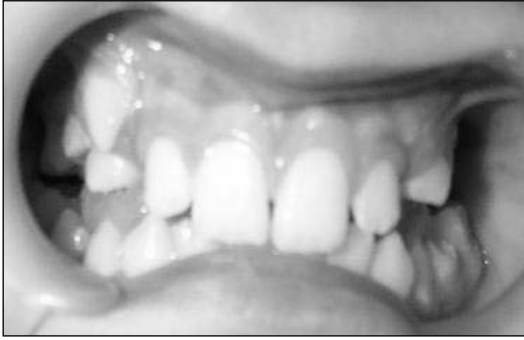The dental transposition occurs more often between the superior canine and first premolar (70%) – *Figures 1,2,3,4* – following the one between the upper canine and the lateral incisor (20%) – *Figures 5,6* and the one between the lower canine and the

lateral incisor (10%) – *Figure 7*. [7,11-17].

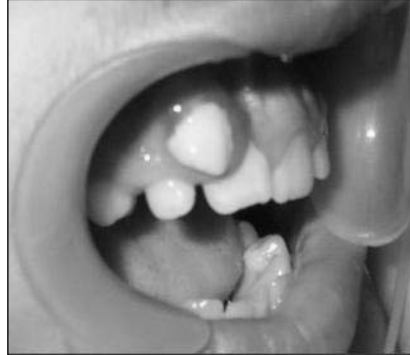A complete or incomplete transposition may be found. When each tooth is aligned instead of its neighbor we talk about complete transposition. This produces minimum disturbances, such as some physiognomic distress when the canine has a sharp cusp: in the canine-lateral incisor transposition, or premature contacts. The partial or incomplete transposition produces more severe disturbances. More seldom, one of them is situated on the arch line and the other is ectopic, labial / buccal or palatal. More frequently, the arch line passes between the two teeth. There may be found an incomplete transposition affecting only the crowns or only the roots. Incomplete transposition produces severe malpositions with space deficiency leading to occlusal and TMJ dysfunction. It may also have a high physiognomic impact and the mastication may be affected following the inflammation of the papillae [14,16,18,4].

It is interesting to notice the higher prevalence of dental transposition in certain syndromes such as Down and Mc Cune Albright [19,20].

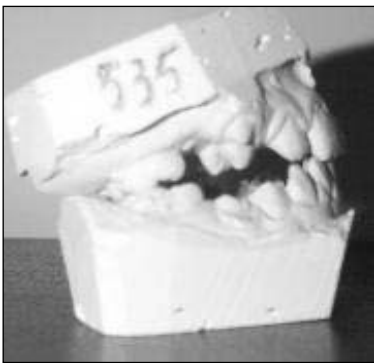**Figure 1.** Incomplete transposition 14/13



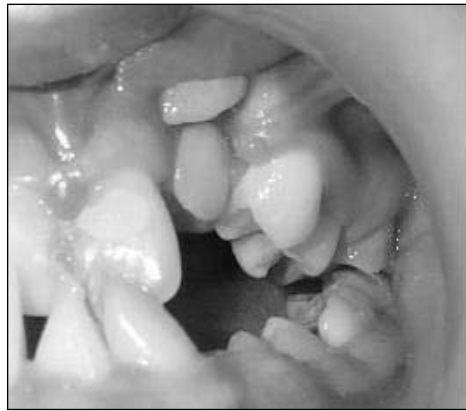**Figure 5.** Incomplete transposition 13/12



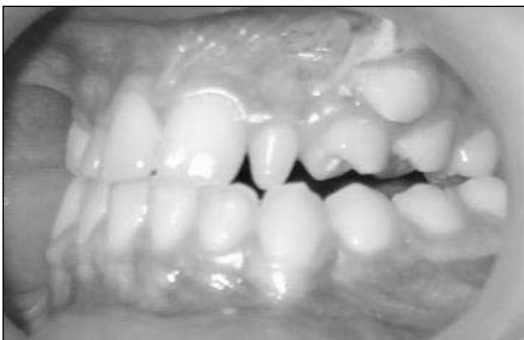**Figure 2.** Incomplete transposition 14/13



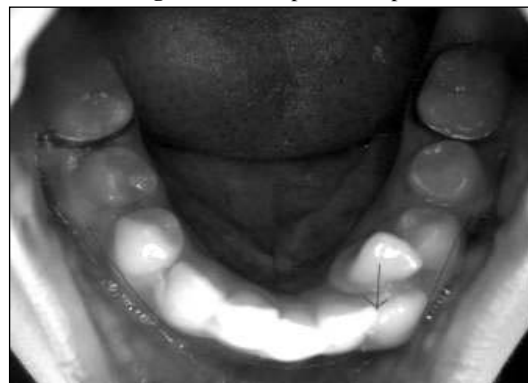**Figure 6.** Intraosseous transposition 23/22



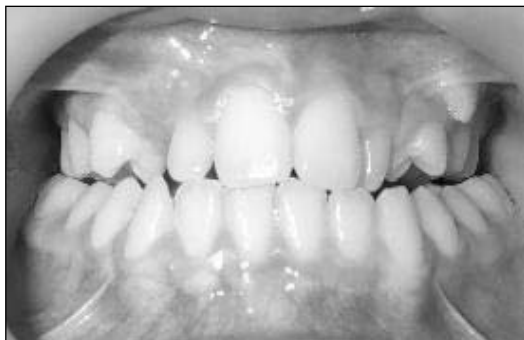**Figure 3.** Incomplete transposition 14/13



**Figure 7.** Incomplete transposition 23/22



**Figure 4.** Incomplete transposition 14/13



## Objectives

This article contains a statistic study that shows the frequency of this anomaly in the local population comparing to the one existing in other countries.

**Material and method**

The study group consisted of 700 subjects who sought treatment during 4 years, between the years 2002-2005. A special characteristic of the studied batch is that all subjects presented different forms of dento-maxillary anomaly.

Out of the initial study group of 700 subjects the ones presenting dental transposition were selected. This secondary batch was particularly investigated, using mainly the study cast and radiographs.

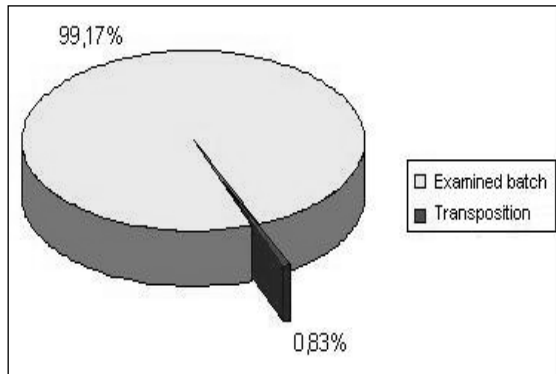
**Results**

Out of the total number of 700 subjects, 119 presented with different forms of dental transposition, representing a percentage of 0.83% - *Chart 1*.

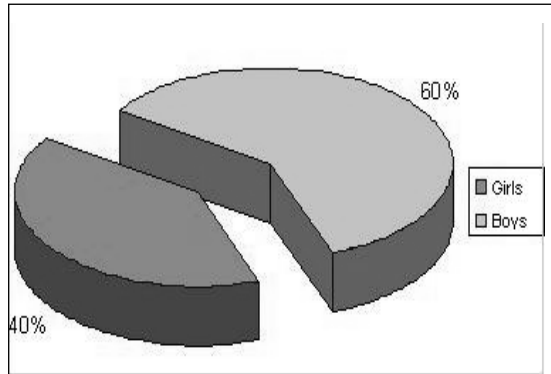
Regarding the sex distribution, a higher frequency in boys than girls by a significant difference of 20% was noticed - *Chart 2*. The anomaly is found to be more frequent in the upper jaw (90%), but may exist at the mandible too (10% - *Chart 3*).

A superior canine-premolar transposition was found in 70% of the cases, followed by 20% with a superior canine-lateral incisor transposition and 10% with an inferior canine-lateral incisor transposition - *Chart 4*.

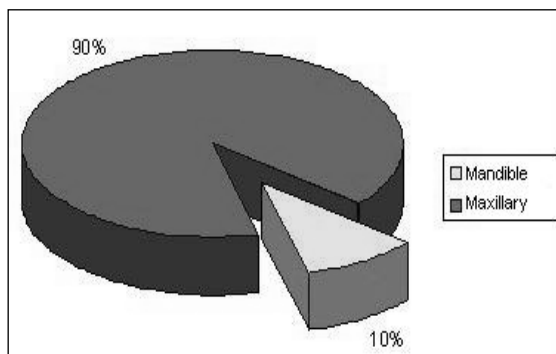
**Chart 1.** Transposition frequency relating to the studied batch



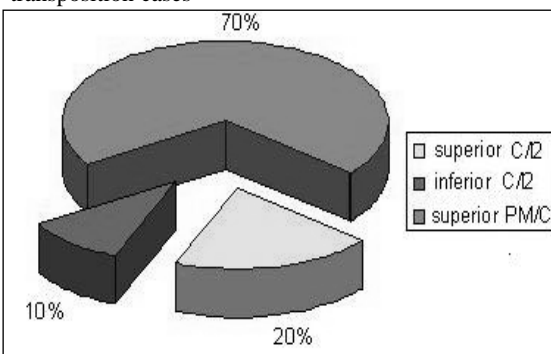
**Chart 2.** Sex distribution of the transposition



**Chart 3.** Maxillary distribution of the transposition



**Chart 4.** Topographic distribution of the transposition cases



## Discussion

The percentage found in our study seems to be quite small, within the limits reported in other studies. At present, in western countries a variation between 0.5% and 2.5% is reported.

The most affected was the superior canine (90%). This involves its neighbors in the transposition, most frequently the superior premolar in 70% of the cases, then the upper lateral incisor (20%).

## Conclusions

The tooth transposition has a various etiology; some authors consider its hereditary

cause, others show the role the tooth and the size of the dental arch play in causing this anomaly.

The dental transposition is an anomaly affecting our population in a percentage of 0.83%, within the limits reported in western countries (0.5-2.5%).

A higher prevalence in girls than boys by 20% was noticed; this could be explained by a higher interest in the way they look like.

The dental transposition affects the canine and its neighbors, the upper one more often than the lower one.

## References

1. Chatopadhyay A. Transposition of teeth and genetic etiology. *Angle Orthod.* 1998; **66**: 147-152.
2. Peck S, Peck L. Classification of maxillary transpositions. *Am J Orthod Dentofacial Orthop.* 1995; **107**: 505-517.
3. Peck S, Peck L, Kataja M. Mandibular lateral incisor-canine transposition, concomitant dental anomalies, and genetic control. *Angle Orthod.* 1997; **68**: 455-466
4. Roman C. *Compendiu de ortodontie – curs universitar destinat studentilor stomatologi.* Ed. Ovidius University Press, 2003; pp 183-186.
5. Mader C, Konzelman JL. Transposition of teeth. *J Am Dent Assoc.* 1979; **98**: 412-413.
6. Parker WS. Transposed premolars, canines, and lateral incisors. *Am J Orthod Dentofacial Orthop.* 1990; **97**: 43-48.
7. Joshi MR, Bhatt NA. Canine transposition. *Oral Surg Oral Med Oral Pathol.* 1971; **31**: 49-54.
8. Stafne EC. *Oral Roentgenographic Diagnosis.* 3<sup>rd</sup> ed. Philadelphia, PA: WB Saunders. 1969; p 27.
9. Segura JJ, Hattab F, Rios V. Maxillary canine transpositions in two brothers and one sister: associated anomalies and genetic basis. *ASDC J Dent Child.* 2002; **69**(1): 54-58, 12
10. Peck L, Peck S, Attia Y. Maxillary canine-first premolar transposition, associated dental anomalies and genetic basis. *Angle Orthod.* 1993; **63**: 99-109.
11. Joshi MR, Gaitonde SS. Canine transposition of extensive degree: a case report. *Br Dent J.* 1966; **121**: 221-222.
12. Ruprecht A, Batniji S, El-Neweihi E. The incidence of transposition of teeth in dental patients. *J Pedod.* 1985; **9**: 244-249.
13. Goyenc Y, Karaman I, Gokalp A. Unusual ectopic eruption of maxillary canines. *J Clin Orthod.* 1995; **4**: 80-82.
14. Shapira Y, Kuftinec M M. Maxillary tooth transposition: characteristic features and accompanying dental anomalies. *AJO/DO*, 2001; **119**(2): 127-134.
15. Hakan T, Sayin MO, Yilmaz HH. Maxillary canine transposition to incisor site: a rare condition. *Angle Orthod* 2005; **65**(2): 284-287
16. Maia FA. Orthodontic correction of a transposed maxillary canine and lateral incisor. *Angle Orthod.* 2000; **70**(4): 339-348.
17. Talbot TQ, Hill AJ. Transposed and impacted with ipsilateral congenitally missing lateral incisor. *Am J Orthod Dentofacial Orthop.* 2002; **121**(3): 316-323.
18. Plunkett DJ, Dysart PS, Kardos TB, Herbison GP. A study of transposed canines in a sample of orthodontic patients. *Br J Orthod* 1998; **25**(3): 203-208.
19. Ely et al. Dental transposition as a disorder of genetic origin. *European Journal of Orthodontics Online* 2005; **10**: 92.
20. Shapira J, Chaushu S, Becker A. Prevalence of tooth transposition, third molar agenesis and maxillary canine impaction in individuals with Down syndrome. *Angle Orthod.* 2000; **70**: 290-296.

Correspondence to: Dr. Constantina Roman, Assoc. Prof., Department of Orthodontics, Faculty of Dental Medicine and Pharmacy, "Ovidius" University of Constanta, Romania. Ilarie Voronca street, no. 7, 900684 Constanta, Romania. E-mail: roman.constantina@yahoo.com