

Phenotypic aspects of DMA in two patients with Laurence-Moon-Biedl syndrome

Marta Girdea, Dragos Totolici, Irina Totolici, Iuliana Dimofte, Corneliu Amariei
Constanta, Romania

Summary

The variable manifestations of this syndrome were initially described by Laurence and Moon and the clinical phenotype was further delineated and popularized by Bardet and Biedl in the 1920's. We emphasized the major features of DMA which provide important insight into understanding the genotype-phenotype correlation in Laurence-Moon-Biedl syndrome. Genetic investigations were made in collaboration with the Department of Medical Genetics of the Faculty of Medicine, "Ovidius" University, Constanta.

Key words: Laurence-Moon-Biedl syndrome, DMA phenotype, facial dysmorphism, caryotype.

Introduction

The natural history of this condition is poorly outlined in the literature. The mental deficiency is usually mild to moderate, and the retinal degeneration generally results in problems of night vision during childhood, even by three years of age. There may also be neurological evidence of spinocerebellar degeneration or cranial nerve palsy [1]. Apparently obesity does not become a problem until early childhood. Hypogonadism has been described as primary germinal hypoplasia and also as hypogonadotropic in type. It is important to appreciate that many of the patients undergo a spontaneous adolescent change [2,3].

The finding of high incidence (27%) of parental consanguinity and the multiple sib involvement are indicative of autosomal recessive mode of inheritance [4]. An occasional parent or collateral relative may show a partial expression, suggesting that the heterozygote may sometimes show abnormality.

Objective

Our study proposes to identify the major phenotypic cranio-facial aspects and of DMA in two patients with this syndrome. In addition, the patient was investigated by genetic analyses and psychological test Raven for establishing the I.Q.

Materials and methods

The two patients were examined by Raven's test to establish the IQ value.

Then we made the evaluation of the main somato-clinic characteristics that we compared with the literature data concerning Laurence-Moon-Biedl syndrome.

In addition, we made a clinical estimate of DMA aspects.

Chromosome studies were carried out on PHA-stimulated peripheral blood lymphocytes using high resolution GTG and RBG banding techniques.

Results

Case 1

Patient S.C., 23 years, sex: female.

At Raven's test the first patient (S.C.) obtained 5 points, IQ = 45, therefore she has mild mental retardation. She is in a hospital with special assistance. She is friendly, hyposensitive to sound, and with mild neurological dysfunction. Perceptual and motor functions are reduced (Figure 1).

Clinical record shows obesity, retinitis pigmentosa, myopia, astigmatism, recurrent urinary tract infections, cardiac murmur, cause unknown, hypogonadism (ovarian hyperplasia) and hypertension.

Facies examination reveals: macrocephaly, depressed nasal bridge, bulbous nose, short

neck, and thick lips (*Figure 2*).

DMA examination showed: lop-sided compression of jaw (class I Angle), reverse lateral right occlusion, lateral vertical inoclusion on the left side, reverse gearing 22, 73/33, persistence of temporary teeth (63), anodontia of 12, 32 detected by Rx examination, deep asymmetric vault, phonetic and physiognomy dysfunction (*Figure 3*).

Caryotype of patient S.C. performed by G mark showed a normal caryotype 46, XX (*Figure 4*).

Case 2

Patient C.M., 18 years old, male.

He obtained 8 points at the Raven test and an IQ = 51, therefore he has a moderate mental retard. He is in a school with special assistance.

The clinical record shows: obesity, retinitis pigmentosa, myopia, convergent strabism, hypogonadism, (small penis and testes), hypertension, chronic nephritis, epileptic crisis, and hyposensitivity to sound.

The cranio-facial phenotype showed: macrocephaly, round face, high forehead, moderate hypertelorism, small nose, small ears, macrostomy, prominent lips, mouth half-open permanently with visibility of the superior incisors (*Figure 5*).

DMA phenotype showed: frontal open bite syndrome (class II/1 Angle), deep vault, persistence of temporary teeth (52,62), trema between inferior central incisors, chronic gingivitis, enlarged tongue, TMJ dysfunction, physiognomic and phonetic dysfunction (*Figure 6*).

Family investigation reveals that the patient is the second child of non-consanguineous parents. The first child died, probably because of intercurrent illness, and the third child has an easy mental retard and he suffers from epilepsy (*Figure 7*).

Discussion

We estimated that obesity, moderate mental retard, retinitis pigmentosa, and hypogonadism present in those two patients (considered to be the main phenotypic aspects of this syndrome), [5] justified us to support a presumptive diagnosis of Laurence-Moon-Bield syndrome.

Regarding facial and DMA dysmorphism, these, although of considerable gravity, have no importance in diagnosing this syndrome, but they confirm the fact that any genetic anomaly has impact on DMA growth and development.

The other phenotypic aspects confirm data from literature, which certify that this syndrome is accompanied by a great variety of anomalies.

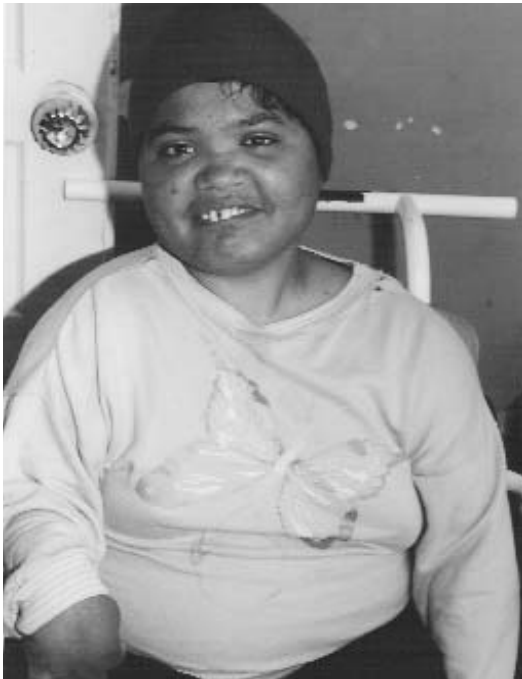

Figure 1. General phenotype

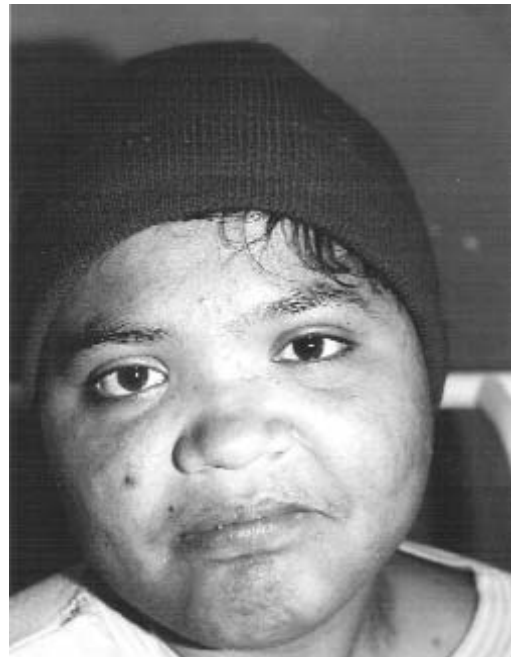

Figure 2. Facial phenotype of patient S.C.

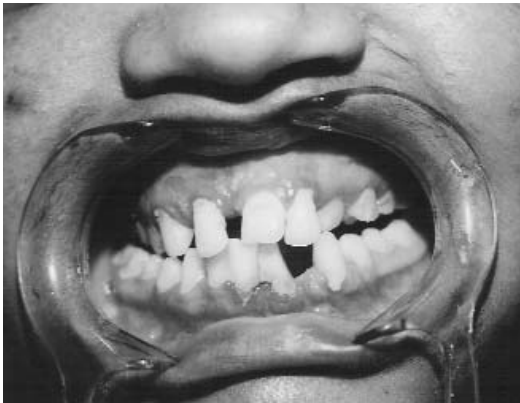

Figure 3. DMA phenotype of patient S.C.

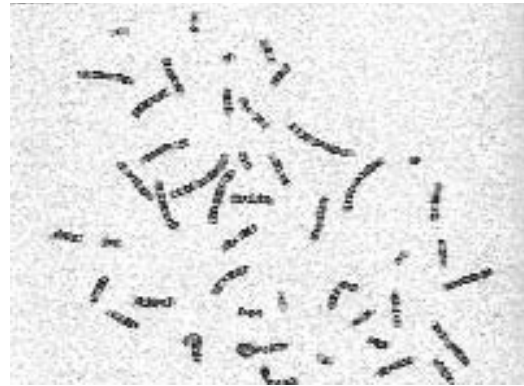


Figure 4. Normal karyotype 46, XX of patient S.C.

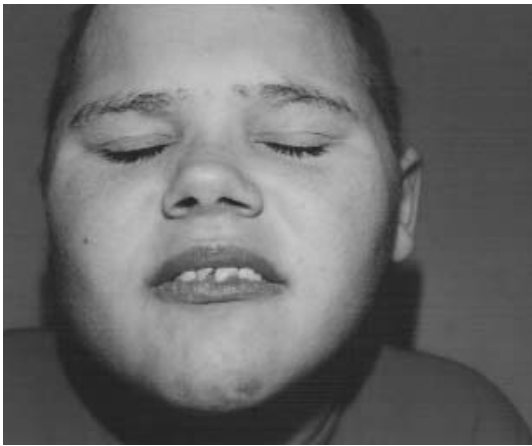

Figure 5. Facial phenotype of patient C.M.

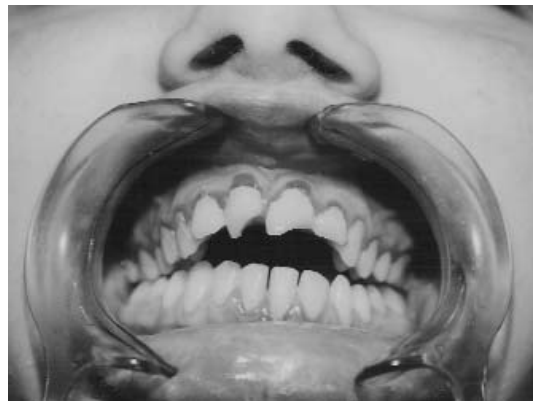

Figure 6. DMA phenotype of patient C.M.

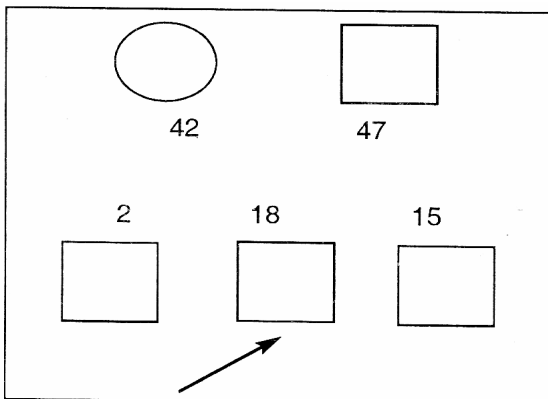


Figure 7. Family investigation of patient C.M. (este figura de mai sus, cu patrate si cifre)

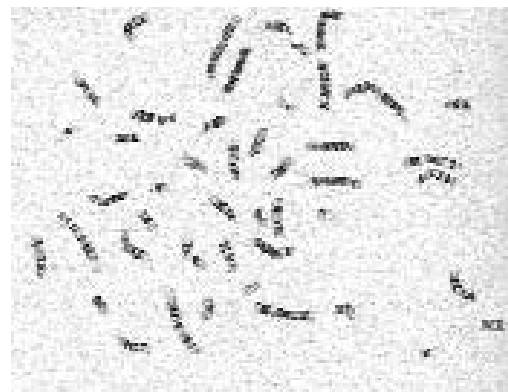


Figure 8. Karyotype of patient C.M., performed by G mark, showed a normal karyotype 46, XY.

Conclusions

1. In supporting this diagnosis, we estimated that obesity, moderate mental retard, retinitis pigmentosa, and the hypogonadism present in those two patients (considered to be the main phenotypic aspects of this syndrome – Green J.S., 1989), justified us to support a presumptive diagnosis of Laurence-Moon-Biedl syndrome.

2. Regarding the facial and DMA dysmorphism, these, although of considerable gravity, have no importance in diagnosing this syndrome, but they confirm the fact that any genet-

ic anomaly has effect on DMA growth and development.

3. Progress in the understanding of the etiology and pathogenesis of many disorders has made the possibility for prenatal diagnosis; most prenatal diagnoses are offered to enable parents in managing their reproductive risk.

4. It is important for the dentist to recognize a genetic autosomal syndrome after dento-maxillary anomalies in association with other general signs.

References

1. Jones Smith's: Recognizable patterns of Human malformations, 5th edition, Saunders Company, 1981: 721.

2. Hurley, R.M. et al: The renal lesion of the Laurence-Moon-Biedl syndrome. *J. Pediatr.*, 1975; 87: 206.

3. Klein, D. and Ammann F.: The syndrome of Laurence-Moon-Bardet-Biedl and allied diseases in Switzerland: Clinical, genetic and epidemiological studies. *J. Neurol. Sci.*, 1969; 9:

479.

4. Laurence J.Z., and Moon, R.C.: Four cases of "retinitis pigmentosa" occurring in the same family, and accompanied by general imperfections of development. *Ophth. Rev.*, 1965, 2:32.

5. Green, J.S. et al: The cardinal manifestations of Bardet-Biedl syndrome, a form of Laurence-Moon-Bardet-Biedl syndrome. *N. Engl. J. Med.*, 1989; 321: 1002.