

## Prophylaxy and screening of oral cancer - a goal of utmost consequence

Cherana Gioga, Ion Niculae, Corneliu Amariei  
Constanta, Romania

### Summary

Malignant neoplasia remains one of the main causes of mortality on an international level and that is why its prophylaxy should receive maximum attention. Oral and maxillo-facial cancer, although representing only 2-5% of all cancer that can affect the human body, has a serious impact on patients because of the infirmity caused by the disease and its treatment and also by the mutilant character of the sequelae; this is another reason why the prophylaxy and screening are both highly consequential.

The role of the local factors (mechanical, irritative, biological, etc.) has already been proved to favour the onset and progress of these lesions, and also it is very well known that the dental surgeon can eliminate these favourising factors. That is why the creating and approving of a prophylaxy and screening plan is of great necessity.

**Key words:** oral cancer, prophylaxy plan, screening plan.

### Introduction

"Prevention is better than cure" - a principle of great application in oncology. A basic role in preventing the appearance of oral malignant tumor belongs to stomatologists, but for them to be able to put their knowledge into practice, an economical, financial and legal status has to be created.

This way the approval and the hightening of a minimal prophylaxy plan and also of a preventive oncological examination should be imposed on the list of medical procedures covered by the National Medical Insurance Company.

### Etiology of oral and maxillo-facial malignant tumors

To prevent a disease, of any kind, we should know its etiopathogeny. It is very difficult to arrange all the theories and hypotheses in logical and absolutely objective order as to the nature, causes and mechanisms of malignant transformations, and for this reason we will stress the role of local factors that are part of prophylaxy plan stomatologists deal with.

#### *Classification of carcinogenesis factors*

##### **I. Determinant causes**

###### *A. Of primary importance*

###### **a. physical agents [3, 6]**

###### ● radiations:

- electromagnetic: UV, X, GAMA;
- corpuscular: alpha, beta, protons, neutrons, etc.

###### **b. chemical [6]**

- direct carcinogenes;
- pro carcinogenes;
- carcinogenes promotors.

As a chemical structure they can be:

- hydrocarbons and aromatic amines;
- alkilants agents;
- metals, hormones, etc.

###### **c. biological agents**

###### ● viruses

- ARN;
- ADN - human papilloma viruses and herpes simplex (the most probable to produce cancer in human beings).

###### *B. Of secondary importance*

- hereditary determinism [4];
- oral and facial lesions with malignisation potential (*see Table 1*) [3, 8];

##### **II. Favourising causes**

- smoking of cigarettes, cigars, pipes and smokless tobacco use (snuff and chewing tobacco) [3, 6, 8];
- chronical ethilism - drinking of three ounces or more of heavy drinks per day.

Tobacco is a mutant agent which leads to ADN-lesions and alcohol reduces the efficiency of ADN-repairing mechanisms. The combination of the two determines a significant increase of risk for malignant tumors appearance. This explains why heavy smokers and alcoholics present a higher frequency of multiple primary tumors.

- poor oral hygiene and local chronic mechanical irritations provoked by: [3,7,8]
- heavy scale deposits;
- overfilling damaging papillae and surrounding soft tissue;
- old bridges and dentures with sharp edges;
- radicular remains with cutting edges.

All these chemical, biological, mechanical, local irritative factors favorize the malignant degeneration without having an exclusive role.

- immunodeficiency - caused by infection with immunodeficiency virus and other immunosuppression conditions;
- age over 40 years [8];
- environmental factors, eating habits [8];
- previous history of oral cancer [8];
- certain oral sites (*see Figure 1*) [8].

By knowing the favourising factors of oral and maxillo-facial cancers it becomes obvious that these must be suppressed.

We propose a minimal prophylaxy and screening measures plan and putting it into practice clearly belongs to the stomatologist.

**I. Prophylaxy plan**

*A. Thorough treatment of oral cavity*

1. Periodical scaling and hygienization (every 6 months) - free of charge for all age categories.
2. Extraction of all irrecuperable radicular remains with sharp edges, damaging oral soft tissues.
3. Correct filling of teeth which should not overpass the tooth contour and damage the papillae and gum. The old, incorrect, overpassing fillings if not replaced, at least have to be adapted.
4. Prosthetic mobile and fixed appliances, correctly following the prosthetical field, so as

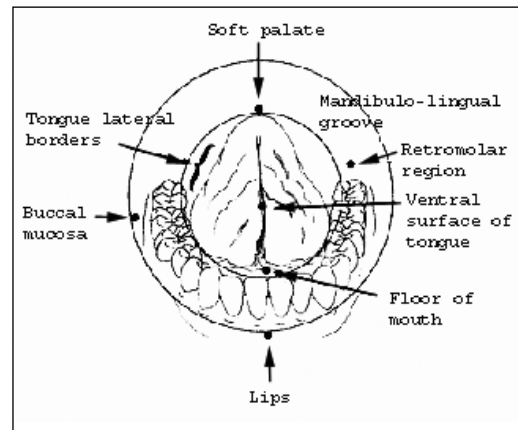
not to produce ulcerations or fibromatosis, gingival hyperplasia, etc.

*B. Permanent medical education based on printed materials explained by doctors and their team*

1. Information with a view to usual oral hygiene and its importance.
2. Information about intrinsic and extrinsic risk factors in tumor progression.
3. Underlining especially the higher risk of malignant tumor onset in the simultaneous presence of several favourising ethiological factors (the main danger being the combination tobacco-alcohol-poor oral hygiene).

**II. Screening plan**

Will be based on the compulsory preventive oncological examination which will consist in periodical detailed study (every 6 months - to each presentation of patients for scaling and hygienization; also free of charge for all adults) of oral-facial area and especially the so called risk area (*Draft 1*).



*Draft 1*

These cases will be reported separately to all pathology, oral pathology and maxillo-facial surgery disciplines, accompanied by specific detailed information such as:

**Table 1.** Lesions at risk of malignancy

<b>Oral</b>	<b>Facial</b>
Erythroplakia	Actinic keratosis
Leukoplakia and erythroleukoplakia	Chronical radiodermatitis
Florid oral papillomatosis	Pseudoepitheliomatotic hyperplasia (Bowen Disease)
Hairy oral leukoplakia (at chronical immuno-suppressed patient e.g. HIV-positive)	Keratoacantoma
Lichen planus	Dubreuilh melanosis
Erythematous lupus	Angular cheylosis

Name Surname	Age	Sex	Living area	Profession	Smoking –	Ethilism –	Type of lesion	
							Unspecific chronic ulcerations	Lesions at risk of malignancy
							Details about onset, treatment and evolution	

After reporting, the cases will be monitored both by dentist, oral pathologist and maxillo-facial surgeon. The latter, before the initiation of therapy will extrainvestigate the cases using:

1. exfoliative cytology [2];
2. toluidine blue staining [5];
3. biopsy - excisional
  - incisional
  - aspiration biopsy (FNA - fine-needle aspiration) [1, 9].

To underline once again the importance of early detection of malignant lesions we will present two suggestive clinical cases:

**Case 1**

A 48-years-old female patient comes to the stomatologist complaining of:

- pain in the anterior side of the mouth floor, increased by mastication and phonation;
- ulceration in the anterior mouth floor.

Oral examination reveals an ulceration with pronounced edges, tough base, situated right at the edge of a massive deposit of scale and congestion of mucosa in the area. The patient affirms that the onset of the present disease occurred few months before but it was smaller, softer and painless.

She was sent to OMF surgeon with the presumption of antherior floor of mouth ulcero-destructive tumor. The following were recommended:

- general treatment: painkiller, anti-inflammatory and antibiotal treatment.
- local treatment:
  - scalling and thorough hygienization;
  - oral application of anti-inflammatory and antibiotal solutions and paste.

After 5 days, during medical check-up we noticed that the lesion had disappeared along with its symptomatology. Anyway, for safety, the patient was monitored (monthly check-up) for 6 months (*Figure 1*).

**Case 2**

A 58-years-old female patient comes to the dentist to have her denture repaired, to have two broken teeth replaced. During the oral examination the doctor notices that the denture cannot even be removed from the prosthetical field, being simply stuck in a mass of hyperplazic fibromatous tissue which fills up the superior buccal area from 14 to 25.

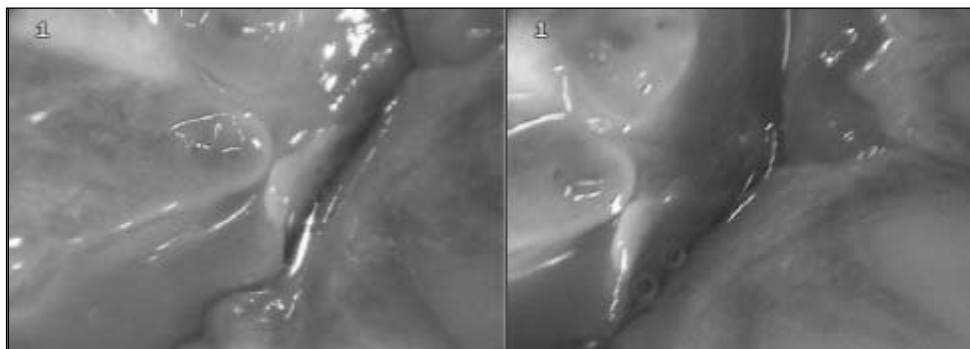
In some places, the tumoral tissue present-ed reduced exulcerations covered by serofibrotic deposits. The stomatologist sends the patient to the OMF surgeon with presumption of upper jaw ulcero-vegetant tumor.

General antibiotal and antiinflammatory treatment was recommended; biopsy samples from different points of the tumor revealed an in situ carcinoma. This was followed by an excision within oncological security limits and the evolution was favorable. The dentist made a denture adapted to the new clinical situation.

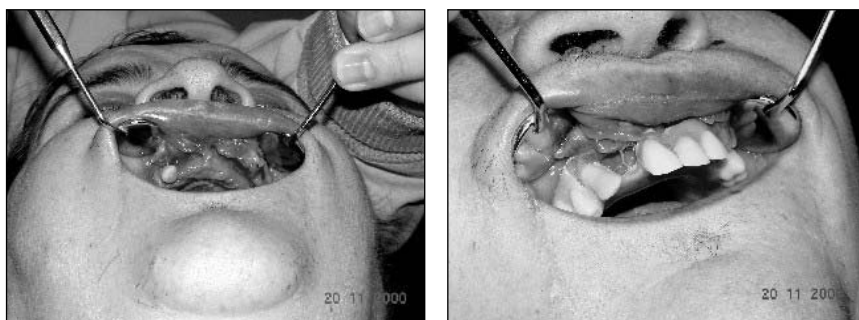
Monthly check-up for the next two years shows favorable evolution (*Figure 2*).

**Discussion**

In both cases the promptness of the specialists was beneficial for the patients because withouth a quick and proper treatment their evolution could have been serious, both floor of the mouth and upper jaw cancer having a poor prognosis.



**Figure 1**



**Figure 2**

It was mentioned that prevention was better than cure, we can add now that it is even cheaper. In the presented cases, the scaling and usual medication (case 1), and excision within oncological limits and a new denture (case 2), have been sufficient without any special problems. On the other hand the surgical and associated treatment necessary in advanced (stage III-IV) mouth floor and upper jaw tumors needs a lot higher costs.

We should also draw the attention on poor life quality of a patient mutilated by the maxillo-facial cancer sequelae.

## Conclusions

Numerous national and international studies report an increase of frequency and complexity of malignant maxillo-facial tumors, a decrease of the onset age, these being reasons enough that the prophylaxy of these diseases should be considered an achievement of highest consequence.

## References

1. Barnard N.A., Paterson A.W., Irvine G.H. et al. Fine needle aspiration cytology in maxillo-facial surgery - experience in a district general hospital. *Br. J. Oral maxillo-facial surg.*, 1996; **31**: 223-226.
2. Barrett A.P., Buckley D.J., Greenberg M.L., Earl M.J. The value of exfoliative cytology in the diagnosis of oral herpes simplex infection in immuno-suppressed patients. *Oral Surg.*, 1986; **62**: 175-178.
3. Burliba<sup>a</sup> C. et al. Chirurgie oral<sup>a</sup> i maxillo-facial<sup>a</sup>. Editura Medical<sup>a</sup>, Bucure<sup>ti</sup>, 1999.
4. "te<sup>n</sup>escu D., C<sup>l</sup>in G. Genetica i cancerul. Ed. Didactic<sup>a</sup> i Pedagogic<sup>a</sup>, Bucure<sup>ti</sup>, 1996.

The implication of local factors in carcinogenesis is obvious, as well as the fact that the stomatologist can partly eliminate these favourising factors.

The simultaneous presence of several favourising factors raises the risk of the onset and progression of malignant diseases.

The gratuity of scaling and hygienization for all age categories will determine more patients to come to the dentist's. This will result in:

- a better oral health status of the population;
- reducing a part of the favourising factors of tumorigenesis (the achieving of prophylaxy);
- the possibility of putting into practice the screening plan with the advantage of a more exact reporting, better monitorization of positive patients, having as an immediate result an improved evolution of these patients.

This is why we consider that the insurance system in stomatology should be urgently reviewed and upgraded.

5. Epstein J.B., Scully C., Spinelli J.J. Toluidine blue and lugol iodine application in the assessment of oral malignant diseases and lesions at risk of malignancy. *J. Oral Pathol. Med.*, 1992; **21**: 160-163.
6. Horch H.H. et al. Chirurgia ortognatodontica e maxillo-faciale. Unione tipografica - Editrice Torinese, 1994.
7. Lynch M.A., Brightman V. J., Greenberg M.S. *Burket's Oral Medicine Diagnosis and Treatment*. Ed. J.B. Lippincott Company, 1994.
8. Wood N.K., Goaz P.W. *Differential diagnosis of oral and maxillo-facial lesions*. Mosby, 1997.
9. Peterson L.J., Ellis E., Hupp J.R., Tucker M.R. *Contemporary oral and maxillo-facial surgery*. Mosby, 1993.

Correspondence to: Assist. Prof. Dr. Cherana Gioga, Department of Oral and Macillo-Facial Surgery, Faculty of Dental Medicine and Pharmacy, Ovidius University of Constanta, Romania. E-mail: oralart@xnet.ro