

# Non-Instrumented Silver Point Retreatment Using the GentleWave Procedure: A Maxillary Central Incisor Case Report

Randy W Garland

Garland Endodontics, Encinitas, California, United States

## Abstract

**Introduction:** Apicoectomies are indicated for endodontically treated teeth when biological or technical factors such as non-healing periapical lesions, persistent clinical symptoms, separated instruments or silver points and the presence of long posts are present and other treatment options are not recommended. **Background:** A 67-year old female patient was referred for possible apicoectomy after previous endodontic treatment with a large post placement and silver point obturation within the apical third. The patient presented with mild pain of the upper jaw and a periapical lesion. **Methods:** Following conservative endodontic access, the previously placed post was removed utilizing a Roto-Pro™ Rotosonic Scaler Tip and the silver point was removed utilizing a thin ultrasonic tip without touching the canal walls. In an attempt to preserve tooth structure, maintain as much of the original canal anatomy as possible, and reduce the possibility of complications associated with standard endodontic treatment, no instrumentation was utilized. The GentleWave® Procedure was used to remove pulp tissue remnants, debris, smear layer, and bacteria from the entire root canal system. Single cone obturation was completed with gutta-percha and BC Sealer™. **Results:** Post-GentleWave Procedure cone fit radiographs depict a patent canal and post-obturation radiographic assessment displays clinically significant obturation of the non-instrumented canal. **Discussion:** This case report demonstrates the ability of the GentleWave Procedure to clean previously endodontically treated anterior teeth without the use of instrumentation, thereby conserving the natural tooth structure and decreasing the chance of intra-procedure complications as seen in standard endodontic treatment.

*Key Words: Uninstrumented canal, Retreatment, GentleWave procedure, Apicoectomy, Multisonic ultracleaning*

## Introduction

Apicoectomies are required for endodontically treated teeth instead of the preferred non-surgical endodontic therapy when biological or technical factors necessitate this therapy [1]. These biological or technical factors may include, but are not limited to, non-healing periapical lesions, persistent clinical symptoms, separated instruments or silver points and the presence of long posts [1,2]. Success rates for apicoectomies have been reported up to 78% with as many as 4% of endodontically treated teeth requiring this type of surgery [3,4]. Although success rates are relatively high, once the tooth is no longer a candidate for non-surgical endodontic treatment, the alternatives in lieu of apicoectomy are limited to extraction with no replacement or replacement with a fixed prosthesis, removable prosthesis or implant [5]. Due to this, the American Association of Endodontics (AAE) only recommends apicoectomies when no other treatment option is available [2-6].

The GentleWave® Procedure (Sonendo®, Laguna Hills, CA), utilizes Multisonic Ultracleaning™ technology, in which advanced fluid dynamics, acoustics, and tissue dissolution chemistry are applied to clean and disinfect the entire root canal system, even in areas that conventional endodontic treatment cannot reach [7-10]. Tissue dissolution with the GentleWave System was seven times faster as compared to standard endodontic techniques, including sonic and ultrasonic devices [10]. Penetration of sodium hypochlorite into dentin within the apical third was four times more effective with the GentleWave® System than active ultrasonic activation [8]. In addition, the GentleWave System was shown to have minimal dentin erosion [11]. Separated hand files within the apical and middle third of root canals were reported to be removed with the GentleWave System without the need

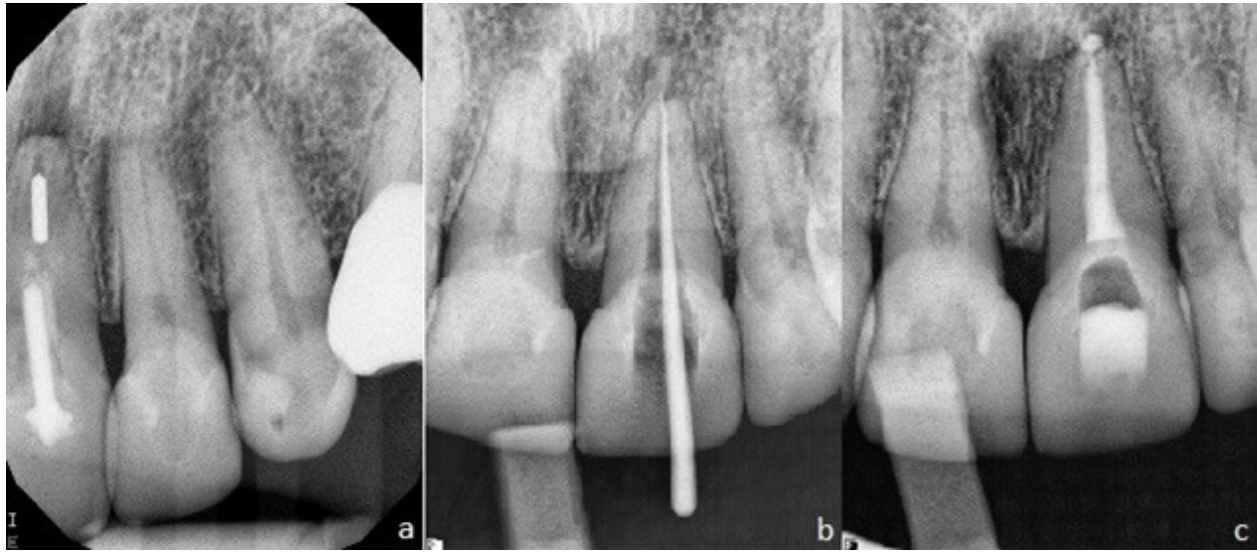
for increased dentin removal [12]. Clinical studies evaluating the GentleWave Procedure have demonstrated high success rates of 97% at 6 and 12-months post GentleWave Procedure [13,14]. In this case report, a non-instrumentation GentleWave Procedure was selected as the best treatment modality for a maxillary incisor with persistent clinical symptoms and apical periodontitis following previous endodontic treatment with an 8mm post and apical obturation with a silver point.

## Case Report

A 67-year-old female was referred for possible apicoectomy. The patient presented with previous endodontic treatment and mild pain of the upper jaw. The patient's medical history was non-contributory.

## Diagnosis

Upon clinical examination of the subject tooth, the maxillary central incisor (#9), was found to have mild pain response to percussion, mild sensitivity to palpation and no presence of mobility or soft tissue lesions. Radiographic analysis revealed previous root canal therapy with a large 8mm post with placement into the middle third of the canal and a silver point placed within the apical third. A periapical lesion was present upon radiographic analysis (Section "a" of *Figure 1*). Based on the clinical and radiographic findings, a diagnosis of symptomatic apical periodontitis was made. Although the referring general dentist suggested apicoectomy, with availability of the GentleWave Procedure for cleaning and disinfection of the root canal system this novel method of endodontic treatment was preferred to retain as much of the natural tooth structure as possible. The endodontic treatment plan and fair prognosis of the tooth was discussed with the patient and the patient consented for treatment.



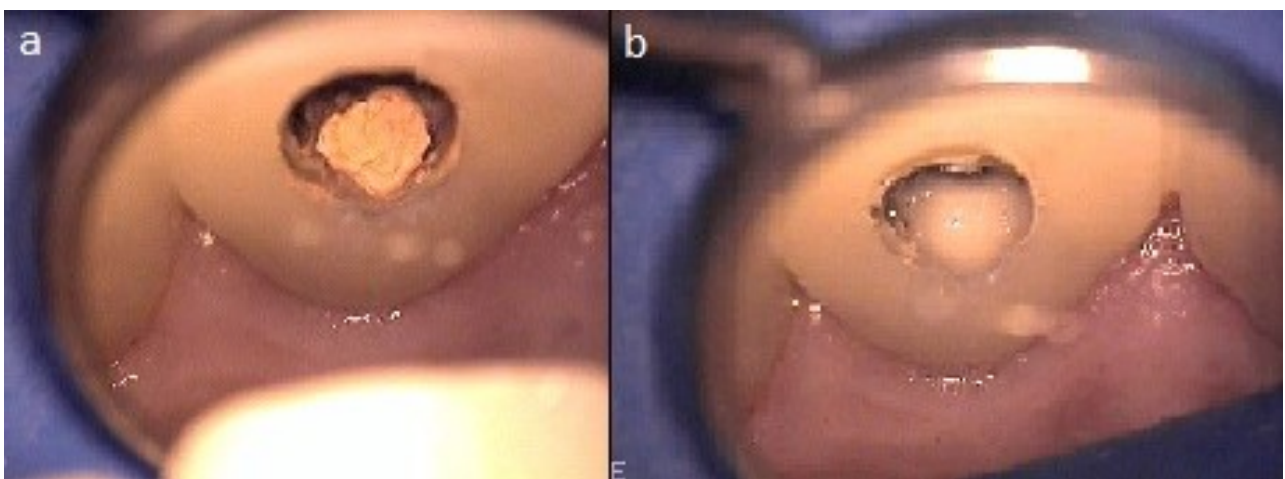
**Figure 1.** Radiograph (a) pre-GentleWave procedure (b) during cone-fit (c) post-GentleWave procedure.

### Procedure

A standard anesthesia protocol was administered, the tooth was isolated with a rubber dam and a dental operating microscope was utilized throughout the procedure. Upon performing conservative, straight-line endodontic access no carious lesions were exposed. Utilizing a Roto-Pro™ Rotasonic Scaler Tip (Ellman International Inc, Hicksville, NY), the titanium post of 8mm in length was able to be removed. Once the canal orifice was exposed, the silver point was visualized within the single canal (Section “a” of Figure 2). By inserting an ultrasonic tip into the canal, the silver point contained within the apical third was able to be vibrated from the canal without contacting any tooth structure. Working length was obtained utilizing cone beam computed

tomography (CBCT) images taken pre-operatively and a gutta-percha try-in radiograph.

In an attempt to preserve tooth structure, maintain as much of the original canal anatomy as possible, and reduce the possibility of complications associated with standard endodontics, no instrumentation was utilized. A temporary build-up was placed utilizing a gingival protectant (Kool-Dam™, PulpDent®, Watertown, USA) to maintain a sealed environment for optimum MultiSonic™ UltraCleaning during the GentleWave Procedure. The GentleWave Procedure Instrument sits on top of the temporary build-up while pulp tissue remnants, debris, smear layer, and bacteria are removed from the entire root canal system (Figure 3).

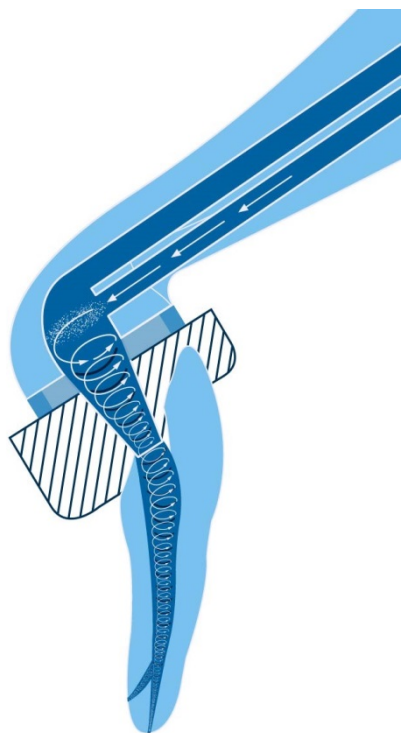


**Figure 2.** Microscope images of pulp chamber (a) prior to and (b) after the GentleWave.

## Discussion

Higher clinical success rates have been reported to correlate with the preservation of the natural root canal anatomy of the tooth during endodontic treatment [15-18]. At the same time, greater effectiveness, cleaning and disinfection rates are associated with the increase of both file diameters and tapers during the instrumentation process to allow for greater debris and biofilm removal, as well as irrigants to penetrate the apical third of the root canals [15-19]. Added to the potential of lower clinical success rates, the increase in file sizes have also been reported to increase the chance of intra-procedure complications [20,21]. Intra-procedure complications include apical transportation, ledge formation, instrument separation, root perforations and root fractures, among others [21-24]. Studies have shown ledge formation occurs in around 50% of endodontic treatments and is one of the most commonly observed procedural errors. Although ledge formation is quite common, it has the potential to prevent adequate shaping, disinfection and subsequently obturation thereby being know for a causal relationship with unfavorable outcomes [23-28]. Another complication which can cause blockage of root canals thus effecting cleaning and disinfection, especially in the apical third, is instrument separation [12]. Instrument separation has seen decreased rates since the invention of rotary and nitinol files, but continues to occur worldwide at a rate of 5% [29]. As instrumentation is increased in endodontics to facilitate irrigation and greater debris and biofilm removal, additional dentin is removed thereby weakening the root. Weakening of the root is common in endodontics, especially when the root is oval, requiring additional instrumentation or canal shaping [30,31]. When extracted teeth that had undergone previous endodontic therapy were analyzed, up to 13.4% were reported to be extracted due to vertical root fractures [21,32]. Root perforations, which can cause bacterial infections from the root canal system or the surrounding periodontal tissue, are reported in 2-12% of endodontically treated teeth [33-36]. These perforations prevent healing and promote inflammatory sequela where the supporting tissue are exposed and have been reported to increase the likelihood of eventual loss of the tooth [34,35]. Due to the increase in intra-procedure complications reported with the increase in file sizes, alternative methods for cleaning and disinfection, such as the GentleWave Procedure, should be endeavored to achieve successful endodontic outcomes.

In this case report, a previously endodontically treated and silver point obturated maxillary central incisor was referred for apicoectomy, but determined appropriate for treatment with the GentleWave Procedure. Haapasalo et al. [10], reported seven times faster tissue dissolution with the GentleWave System than standard root canal techniques including the use of sonic and ultrasonic devices. Sodium hypochlorite penetration in the apical third was four times more effective with the GentleWave® System than active ultrasonic activation, yet the system has been shown to cause minimal dentin erosion [8,11]. In addition, the GentleWave System has been reported to be effective in removing separated hand files from the apical and middle thirds of molar root canal systems without the need for increased dentin removal [12]. Lastly, clinical studies evaluating the



**Figure 3.** The GentleWave® system anterior/premolar procedure instrument.

## Procedure

Afterwards, visualization through the microscope revealed a clean pulp chamber and canal (Section “b” of *Figure 2*) that was subsequently dried with paper points. None of the typical corrosive black sediment from standard silver point retreatment cases was visible when drying the canal with paper points. Obturation was completed utilizing a single cone technique with gutta-percha and BC Sealer (Brasseler USA®, Savannah, GA). A coronal seal was placed and the cavity filled with a glass ionomer (GC Fuji Triage® Alsip, IL). The patient was advised to return to their general dentist for comprehensive dental care.

There was no reported discomfort during or after the procedure. Two days after the procedure, the patient was contacted for post-procedure inquiry. The patient indicated they had not experienced any discomfort since the procedure.

## Results

Pre-procedure radiographs exhibit a titanium post of 8mm in the coronal and middle thirds of the single canal and a silver point within the apical third (Section “a” of *Figure 1*). A periapical lesion is visible on the radiograph. Section “b” of *Figure 1* portrays a cone fit post-GentleWave Procedure radiograph providing evidence of a patent canal without the use of instrumentation. Radiographic review of the post-procedure image (Section “c” of *Figure 1*) displays complete obturation of the non-instrumented canal. A small sealer puff is visible in the periapical region verifying canal patency.

GentleWave Procedure have demonstrated high success rates of 97% at 6 and 12-months post GentleWave Procedure [13,14]. Although many factors would typically require this case to be treated with apicoectomy, including a post greater than 5 mm in length, silver point only within the apical third, persistent apical periodontitis and persistent clinical symptoms, due to the published success rates with the GentleWave Procedure, this endodontic treatment modality was preferred.



**Figure 4.** Post and silver point after removal.

Obturation with silver points was originally introduced in the 1930's due to their simplicity of placement and rigidity [37,38]. Later, studies began to examine the reasons for clinical failures surrounding silver point obturation and found that the silver points lead to corrosion and did not adequately fill the root canal space [39]. Reports soon showed that electrochemical corrosion occurred and that the byproducts of this corrosion were highly cytotoxic [38,40,41]. When silver points are removed, a black sediment is typically seen coating the root canal, this sediment has been reported as being created from this cytotoxic byproduct [41,42]. Typically, after standard root canal instrumentation and irrigation, paper points remain coated with this black sediment even after additional irrigation and paper point usage. Additional time and resources are spent after the cleaning and disinfection phase of a silver point retreatment case in an attempt to remove as much of this corrosive material as possible. In this case, after treatment with the GentleWave Procedure, no black sediment was visible when paper points were utilized to dry the canals, although black sediment was visualized pre-GentleWave Procedure as seen in *Figure 4*. By utilizing the GentleWave Procedure, the case time and resource usage was able to be reduced while, in theory, reducing the possibility of leaving cytotoxic byproduct behind in the root canals.

This case report demonstrates the ability of the GentleWave Procedure to clean previously endodontically treated anterior teeth without the use of instrumentation, thereby conserving the natural tooth structure and decreasing the chance of intra-procedure complications as seen in standard endodontic treatment. Additional recall with the patient may be warranted to assess long-term healing and clinical outcomes. Additional research on non-instrumentation endodontics in retreatment

cases with the GentleWave Procedure is needed to provide evidence for a larger population.

## Acknowledgements

None.

## Disclosure

Dr. Randy Garland is a consultant for Sonendo Inc.

## References

1. El-Swiah JM, Walker RT. Reasons for apicectomies. A retrospective study. *Endodontics and Dental Traumatology*. 1996; **12**: 185-191.
2. Abramovitz I, Better H, Shacham A, Shlomi B, Metzger Z. Case selection for apical surgery: a retrospective evaluation of associated factors and rational. *Journal of Endodontics*. 2002; **28**: 527-530.
3. Torabinejad M, Corr R, Handysides R, Shabahang S. Outcomes of nonsurgical retreatment and endodontic surgery: a systematic review. *Journal of Endodontics*. 2009; **35**: 930-937.
4. Salehrabi R, Rotstein I. Epidemiologic evaluation of the outcomes of orthograde endodontic retreatment. *Journal of Endodontics*. 2010; **36**: 790-792.
5. Von Arx T, Steiner RG, Tay FR. Apical surgery: Endoscopic findings at the resection level of 168 consecutively treated roots. *International Endodontic Journal*. 2011; **44**: 290-302.
6. American Association of Endodontists. Appropriateness of Care, and Quality Assurance Guidelines. 1998.
7. Molina B, Glickman G, Vandrangi P, Khakpour M. Evaluation of root canal debridement of human molars using the GentleWave system. *Journal of Endodontics*. 2015; **41**: 1701-1705.
8. Vandrangi P. Evaluating penetration depth of treatment fluids into dentinal tubules using the GentleWave® system. *Dentistry*. 2016; **6**: 366.
9. Vandrangi P, Basrani B. Multisonic Ultracleaning™ in molars with the GentleWave™ system. *Oral Health*. 2015; **72**: 86.
10. Haapasalo M, Wang Z, Shen Y, Curtis A, Patel P, et al. Tissue dissolution by a novel multisonic ultracleaning system and sodium hypochlorite. *Journal of Endodontics*. 2014; **40**: 1178-1181.
11. Wang Z, Maezono H, Shen Y, Haapasalo M. Evaluation of root canal dentin erosion after different irrigation methods using energy-dispersive x-ray spectroscopy. *Journal of Endodontics*. 2016; **42**: 1834-1839.
12. Wohlgemuth P, Cuocolo D, Vandrangi P, Sigurdsson A. Effectiveness of the GentleWave system in removing separated instruments. *Journal of Endodontics*. 2015; **41**: 1895-1898.
13. Sigurdsson A, Garland RW, Le KT, Woo SM. 12-month healing rates after endodontic therapy using the novel GentleWave system: A prospective multicenter clinical study. *Journal of Endodontics*. 2016; **42**: 1040-1048.
14. Sigurdsson A, Le KT, Woo SM, Rassoulouian SA, McLachlan K, et al. Six-month healing success rates after endodontic treatment using the novel GentleWave™ System: The pure prospective multicenter clinical study. *Journal of Clinical and Experimental Dentistry*. 2016; **8**: e290-298.
15. Da Silva, Limoeiro AG, Dos Santos AH, De Martin AS, Kato AS, et al. Micro-computed tomographic evaluation of 2 nickel-titanium instrument systems in shaping root canals. *Journal of Endodontics*. 2015; **42**: 496-499.
16. Senia ES, Marshall FJ, Rosen S. The solvent action of sodium hypochlorite on pulp tissue of extracted teeth. *Oral Surgery, Oral Medicine, Oral Pathology*. 1971; **31**: 96-103.
17. Salzgeber RM, Brilliant JD. An in vivo evaluation of the penetration of an irrigating solution in root canals. *Journal of Endodontics*. 1977; **3**: 394-398.

18. De-Deus G, Marins J, Silva EJ, Souza E, Blladonna FG, et al. Accumulated hard tissue debris produced during reciprocating and rotary nickel-titanium canal preparation. *Journal of Endodontics*. 2015; **41**: 676-681.
19. Paraskevopoulou MT, Khabbaz MG. Influence of taper of root canal shape on the intracanal bacterial reduction. *The Open Dentistry Journal*. 2016; **10**: 568-574.
20. Haapasalo M, Endal U, Andi H, Coil JM. Eradication of endodontic infection by instrumentation and irrigation solutions. *Endodontic Topics*. 2005; **10**: 77-102.
21. Zadik Y, Sandler V, Bechor R, Salehrabi R. Analysis of factors related to extraction of endodontically treated teeth. *Oral surgery, oral medicine, oral pathology, oral radiology, and endodontics*. 2008; **106**: e31-35.
22. Devale MR, Mahesh MC, Bhandary S. Effect of Instrumentation length and instrumentation systems: hand versus rotary files on apical crack formation - an in vitro study. *Journal of Clinical and Diagnostic Research*. 2017; **11**: ZC15-ZC18.
23. Kapalas A, Lambrianidis T. Factors associated with root canal ledging during instrumentation. *Endodontics and Dental Traumatology*. 2000; **16**: 229-231.
24. Gutmann JL, Dumsha TC, Lovdahl PE, Hovland EJ (1997) Problem solving in endodontics (3rd edn.). Mosby, St. Louis.
25. Cohen S, Burns RC (2002) Pathways of the Pulp (8th edn.). Mosby, St Louis.
26. Harty FJ, Parkins BJ, Wengraf AM. Success rate in root canal therapy: A retrospective study of conventional cases. *British Dental Journal*. 1970; **128**: 65-70.
27. Namazikhah MS, Mokhlis HR, Alasmakh K. Comparison between a hand stainless steel k-file and a rotary NiTi 0.04-taper. *Journal of the California Dental Association*. 2000; **28**: 421-426.
28. Greene KJ, Krell KV. Clinical factors associated with ledged canals in maxillary and mandibular molars. *Oral Surgery, Oral Medicine, Oral Pathology*. 1990; **70**: 490-497.
29. Parashos P, Gordon I, Messer HH. Factors influencing defects of rotary nickel-titanium endodontic instruments after clinical use. *Journal of Endodontics*. 2004; **30**: 722-725.
30. Wilcox LR, Roskelley C, Sutton T. The relationship of the rootcanal enlargement to finger-spreader induced verticle root fracture. *Journal of Endodontics*. 1997; **23**: 533-534.
31. Wu M, R'oris A, Barkis D, Wesselink PR. Prevalence and extent of long oval canals in the apical third. *Oral Surgery, Oral Medicine, Oral Pathology*. 2000; **89**: 739-743.
32. Touré B, Faye B, Kane AW, Lo CM, Niang B, et al. Analysis of reasons for extraction of endodontically treated teeth: A prospective study. *Journal of Endodontics*. 2011; **37**: 1512-1515.
33. Seltzer S, Bender IB, Smith J, Freedman I, Nazimov H. Endodontic failures: An analysis based on clinical, roentgenographic, and histologic findings. *Oral Surgery, Oral Medicine, Oral Pathology*. 1997; **23**: 500-516.
34. Alhadainy HA. Root perforations: A review of literature. *Oral Surgery, Oral Medicine, Oral Pathology*. 1994; **78**: 368-374.
35. Jew RC, Weine SW, Keene JJ, Smulson MH. A histologic evaluation of periodontal tissues adjacent to root perforations filled with cavit. *Oral Surgery, Oral Medicine, Oral Pathology*. 1982; **54**: 124-135.
36. Ingle J (2002) Endodontics (5th edn.). Bc Decker Co, 706, Bakland.
37. Zielke DR, Brady JM, del Rio CE. Corrosion of silver cones in bone: A scanning electron microscope and microprobe analysis. *Journal of Endodontics*. 1975; **1**: 356-60.
38. Chana H, Briggs P, Moss R. Degradation of a silver point in association with endodontic infection. *International Endodontic Journal*. 1998; **31**: 141-146.
39. Goldberg F. Relation between corroded endodontic failures. *Journal of Endodontics*. 1981; **7**: 224-227.
40. Zmener O, Dominquez FV. Corrosion of silver cones in the subcutaneous connective tissue of the rat: A preliminary scanning electron microscope, electron microprobe, and histological study. *Journal of Endodontics*. 1985; **11**: 55-61.
41. Seltzer S, Green DB, Weiner N, DeRenzis FP. A scanning electron microscope examination of silver cones removed from endodontically treated teeth. 1972. *Journal of Endodontics*. 2004; **30**: 463-74.
42. Palmer GR, Weine FS, Palmer MJ, Healey HJ. A study of the tissue reaction to silver cones and Ti-6Al-4V in the rhesus monkey. *Journal of Endodontics*. 1979; **5**: 116-120.