Strategies to Minimise the Consequences of Trauma to the Teeth

Paul V Abbott[1], Jacqueline Castro Salgado[2]

[1]Winthrop Professor of Clinical Dentistry - Program Director (Endodontics), School of Dentistry, The Unviersity of Western Australia - 17 Monash Avenue NEDLANDS WA 6009, Australia. [2]Associate Professor - School of Dentistry, The University of Western Australia, Australia.

Abstract

Trauma to the mouth involves not only the teeth but also the dental pulp, the periodontal ligament, bone, gingiva and other associated structures. There are many different types of injuries with varying severity in each case and often more than one injury to a tooth at the same time. Hence, there are many different potential responses of the pulp, peri-radicular and soft tissues following trauma. The responses of the different tissues are inter-related and dependent on each other, which results in many potential consequences of trauma to the teeth. It is imperative that dentists have a thorough understanding of the possible tissue responses so appropriate treatment can be provided to minimise the consequences of trauma. The five main strategies to reduce these consequences are to: 1) perform a thorough examination and accurate diagnosis to identify all injuries and to assess the likely healing responses; 2) reposition and stabilise the teeth and bones to provide optimum conditions for healing; 3) carefully manage soft tissues to help healing; 4) commence root canal treatment immediately in specific situations to prevent external inflammatory resorption; and 5) follow-up and review all traumatised teeth to identify and manage any adverse consequences as soon as they occur in order to minimise their effects on the patient.

Introduction

Trauma to the teeth is a relatively common occurrence [1]. Some studies suggest that every second person will experience some form of dental trauma by the age of 14 years with approximately 30% of the injuries involving deciduous teeth and 22% involving permanent teeth [1-3]. Fortunately, the most common injuries are relatively minor, being uncomplicated crown fractures, concussion and subluxation [4,5]. This review will only discuss trauma to the permanent dentition.

A patient who has suffered trauma to the teeth may present as an emergency and in many cases the accident occurs out of normal office hours for most dentists [4,6,7]. Hence, the patients may present to a hospital or other medical centre where a dentist may not be readily available to provide appropriate care. In addition, and partly as a result of the above, most dentists do not regularly provide emergency treatment for injuries to the teeth and this may lead to uncertainties about what is the most appropriate treatment for each injury. All of these factors can lead to delays in treatment or inappropriate treatment, both of which may have negative consequences on the prognosis of the injured teeth. The long-term prognosis of teeth that have been damaged is very dependent on the emergency management and how quickly this is provided.

Upper central incisors are the most commonly injured teeth and boys tend to have trauma twice as often as girls [1-5]. The peak age ranges for dental injuries are between 2-4 years and 8-10 years [1,2]. The significance of these ages is important to note. In the 2-4 year age group, the injury occurs to the deciduous teeth but the underlying permanent teeth are developing and their development may be affected by some injuries to the deciduous teeth (e.g. intrusion, avulsion, etc). Typical developmental defects include enamel defects such as hypoplasia and root dilacerations. In the 8-10 year age group, the permanent incisors are not fully developed, especially in boys, where there may be short roots, thin dentine walls and open apices. The incomplete root development may be advantageous in that pulp revascularisation is more likely to occur, compared to fully developed teeth [8], or it may be a disadvantage such as when pulp necrosis and infection of the root canal system occurs. Such teeth will have a poorer prognosis due to the lack of dentine in the tooth root and they will require extensive or complicated endodontic procedures [9].

As outlined by Lauridsen et al. [10], there are six types of luxation injuries plus nine types of fractures that can occur to the teeth and each is a unique injury to the soft and hard tissues. There are often concurrent injuries - such as a luxation and a fracture – with 54 possible combinations and thus 54 different scenarios for healing. In addition, there are 19 cellular systems in the dental organ and these can all have different healing responses and potentials [10]. Thus, the consequences of injuries to the teeth and their surrounding tissues can range from very little to very complex.

Some injuries may have no, or only minor, long-term consequences. As an example, an enamel infraction may not have any long-term effects on the tooth and may only require monitoring to ensure that no problems develop such as pulp necrosis and infection of the root canal system. Similarly, a tooth with a concussion injury may only require reviews to monitor it in the long-term. On the other hand, some dental injuries can have severe long-term consequences that require complex and continuing management - for example, a tooth with a complicated crown-root fracture may require root canal treatment, periodontal surgery, a post-retained core and a full crown restoration plus long-term reviews and maintenance. Such a restoration and the root canal filling may also require replacement at various times throughout the patient's life. Another example of an injury with complex and severe consequences is an avulsed tooth that has been replanted. Initially such a tooth may show some healing but later may develop external replacement resorption and ankylosis, leading to extraction and the need for prosthesis such as an osseointegrated implant and a crown restoration, which will then require long-term reviews and maintenance.

Corresponding author: Paul V Abbott, Winthrop Professor of Clinical Dentistry, School of Dentistry, 17 Monash Avenue NEDLANDS WA- 6009, Australia, Tel: +61 8 9346 7636; Fax: +61 8 9346 7666; e-mail: paul.v.abbott@uwa.edu.au

Tissue Responses to Trauma

The dental pulp and the peri-radicular tissues can both be affected by trauma to the teeth [10]. The responses of these tissues will determine the treatment required and the outcome of the teeth. Hence, it is important to consider the various responses that can occur in these tissues.

Responses can be favourable or unfavourable in nature. Favourable responses do not generally require any treatment and therefore the management required is simply regular reviews to monitor the teeth over time and ensure there are no changes in the state of the tooth or its associated tissues that require treatment. On the other hand, unfavourable responses will require some form of treatment, depending on the actual response of the tissue. Therefore it is essential to understand the nature of each possible response and its consequences, as well as how to manage them.

Tables 1-3 summarise the possible responses of the pulp, the root canal system, the peri-radicular tissues and the soft tissues following trauma to a tooth. It is important to note that each possible response should not be considered individually or as a final, long-term response to the injury since two or more responses may occur simultaneously or sequentially over time. For example, a pulp may initially recover following an uncomplicated crown fracture but then it may subsequently become necrotic and infected if bacteria are able to enter the tooth/pulp system (such as when the restoration breaks down). Another example is an avulsed tooth that develops both external inflammatory and replacement resorption simultaneously and then subsequently ankylosis. Furthermore, the pulp response cannot be isolated from the peri-radicular or soft tissue responses. Although they are separate entities with different responses to the injury, a response of one tissue may affect the response of another tissue. For example, if the root canal system is infected and there has been extensive damage to the root surface and/or external surface resorption, then external inflammatory resorption is likely to occur. Hence, the entire healing scenario is potentially very complex [10].

Table 1. *Possible responses of the pulp and root canal system following trauma to a tooth.*

Responses of the Dental Pulp and Root Canal System to Trauma
Favourable Responses
• Recovery and return to normal • Pulp fibrosis • Pulp canal calcification
Unfavourable Responses
• Pulp necrosis • Infection of the root canal system • Internal root resorption - Surface, Inflammatory and/or Replacement • Combinations of the above - Simultaneously and/or Sequentially over time

Table 2. *Possible responses of the peri-radicular tissues following trauma to a tooth.*

Responses of the Peri-radicular Tissues to Trauma
Favourable Responses
• Recovery and return to normal • Fibrous healing • Transient apical breakdown
Unfavourable Responses
• Cessation of root development • Disturbances to root development • Bone resorption - Crestal, Apical and/or Lateral • External root resorption - Surface, Inflammatory, Replacement and/or Invasive • Ankylosis - With or Without Root Resorption • Combinations of the above - Simultaneously and/or Sequentially over time

Table 3. *Possible responses of the soft tissues following trauma to a tooth.*

Responses of the Soft Tissues to Trauma
Favourable Responses
• Recovery and return to normal • Fibrous healing (scar)
Unfavourable Responses
• Loss of attachment • Gingival recession • Combinations of the above - Simultaneously and/or Sequentially over time

Factors Affecting the Responses to Trauma

Table 4 lists the mechanical and biological factors that can affect the responses of tissues following trauma to the teeth. The mechanical factors will indirectly affect the responses to trauma since they determine the type of injury and its severity whereas the biological factors have a more direct effect on the tissue responses [1].

It is essential that clinicians obtain a detailed history from the patient (or parent of a child patient) regarding how the injury occurred [11,12]. This will alert the clinician to the possible injuries that may be present which will facilitate the examination procedure. This also requires that the clinician must have a thorough understanding of the mechanical factors and how they lead to different injuries.

The absence, or the presence and extent, of the biological factors should be determined during the initial examination following the injury. Radiographs are an essential part of the examination [11-13] since they reveal injuries that are not clinically evident (for example, a horizontal root fracture) and they also help to determine whether the biological factors will play a role in the recovery of the tooth and its associated tissues. In particular, radiographs will show the stage of root development, the degree of displacement (if any) of the tooth, the extent of pulp involvement and whether there are concurrent injuries on the same tooth. In order to fully assess all injuries, multiple radiographic views are essential [13].

Table 4. *Mechanical and biological factors that can affect the responses of tissues following trauma to a tooth.*

Mechanical Factors	Biological Factors
• Direct or Indirect trauma • Energy of impact - includes Mass and Velocity • Resiliency of the impacting object • Shape of the impacting object • Direction of the impacting force	• Stage of root development • Extent of pulp involvement • Degree of displacement of the tooth • Concurrent injuries to the same tooth

The biological factors particularly influence the ability of the pulp to recover following treatment. If the root is not fully developed, then pulp revascularisation is more likely to occur [14] and root development can proceed. This will improve the long-term prognosis of the tooth as more dentine is produced by the pulp resulting in a "stronger" tooth that is less likely to fracture [15], particularly if traumatised again. Hence, an incompletely developed tooth should be managed with the aim of preserving the pulp.

The degree of displacement is a major factor affecting both the pulp [8,14] and the periodontal ligament (PDL) healing [8,16]. Teeth with no or little displacement (luxation) have a far better prognosis as there is no or little reduction of the pulp's blood supply and no or little damage to the cementum and the PDL. Hence, concussion or subluxation injuries have the most favourable prognosis, followed by extrusion, lateral luxation, intrusion and avulsion [8,14,16].

The extent of involvement of the pulp is a factor but not to the extent that many clinicians believe. Cvek has shown that even large pulp exposures and pulps exposed for long periods of time can recover if adequately treated such as with a partial pulpotomy [17,18]. However, it may not always be possible to do a partial pulpotomy as teeth with larger pulp exposures associated with extensive crown or crown-root fractures may require more radical treatment such as pulp removal and root canal treatment to enable the tooth to be restored adequately.

Concurrent injuries to the same tooth imply that more tissues will be involved than if there is only one injury. It is relatively common for teeth to have concurrent injuries – such as a crown fracture and a luxation injury at the same time [19,20]. In these cases, the pulp may be compromised because of the crown fracture and possible bacterial contamination at the critical time when the pulp's blood supply is either reduced or severed completely by the luxation injury, resulting in a higher chance of pulp necrosis and infection of the root canal system.

Strategies to Reduce the Consequences of Trauma to the Teeth

As outlined above, there are many potential consequences of trauma to the teeth. The most serious and complicated of these are pulp necrosis and infection of the root canal system, external inflammatory root resorption, external replacement root resorption, ankylosis, bone resorption, loss of attachment and gingival recession. Many of these are inter-related – such as infection of the root canal system, external inflammatory resorption and bone loss (and possibly attachment loss and gingival recession) but they can be largely prevented by various treatment procedures. However, some of these consequences of trauma cannot be prevented - such as external replacement resorption and ankylosis - and they occur because of the damage induced during the accident. The remainder of this paper will concentrate on outlining strategies that can be used to prevent or reduce the consequences of trauma to the permanent teeth, and it will not discuss the other problems that may occur. Five key strategies will be discussed in detail – examination and diagnosis, repositioning and stabilisation of the teeth and bones, soft tissue management, immediate root canal treatment in specific situations to prevent external inflammatory resorption, and follow-up of all traumatised teeth to identify and manage any adverse consequences as soon as possible.

Strategy No. 1 - Examination and diagnosis

The first strategy to help reduce the consequences of trauma to the teeth is to fully assess the injuries that are present. This requires a thorough history as well as a complete clinical and radiographic examination [11-13]. The examination should also include tests such as pulp sensibility tests, percussion, palpation, mobility, periodontal probing, etc.

Radiographs are essential to reveal all injuries as well as other important factors affecting healing (see above). The radiographic examination should consist of at least three periapical radiographs and an occlusal radiograph of the arch that has suffered the obvious trauma, plus radiographs of the opposing arch as there may be injuries that are not immediately obvious [11-13]. Other imaging techniques may also be of value although they may not always be readily available or may not be required immediately – such as CT scans, cone beam CT's etc.

Pulp sensibility testing is essential [11-13] and there is no excuse not to do these simple tests at the time of the initial presentation after trauma. Some clinicians have argued in the past that such tests are unreliable immediately after trauma since the pulp is "in shock" and will not give reliable responses. However, whilst this may be possible, there is no scientific evidence for this assumption. In contrast, there is evidence that indicates the immediate responses to pulp sensibility tests are good indicators of the long-term prognosis of the pulp [11-13] – for example, very few teeth that responded to pulp sensibility tests immediately following concurrent concussion and crown fracture injuries developed pulp necrosis over time, whereas about 50% of teeth that did not respond immediately after these same injuries developed pulp necrosis and infection of the root canal system within six months [21].

It is important to understand that the results of pulp tests performed immediately after trauma should not be used to diagnose pulp necrosis or to indicate immediate root canal treatment since many pulps may recover – as in the above example of concurrent concussion and crown fracture injuries. The immediate pulp test results may also indicate that a tooth has been traumatised when there are no other physical signs of injury. Hence, immediate pulp sensibility testing is essential to provide baseline data for comparison with subsequent tests and to alert clinicians of the possibility of pulp necrosis occurring later [11-13].

A thorough history and examination will lead to a thorough and accurate diagnosis of all injuries present. It is essential to diagnose each injury and each tissue involved - that is, the teeth, bone and soft tissues as well as the state of the pulp and peri-radicular tissues. A thorough diagnosis will then allow all injuries to be effectively managed. An essential part of the examination and diagnostic process is to also record all the details obtained from the history, the clinical examination, the various tests performed, the radiographic examination and all of the final diagnoses.

Strategy No. 2 - Repositioning and stabilisation of the teeth and bones

All tissues that have been displaced or fractured should be

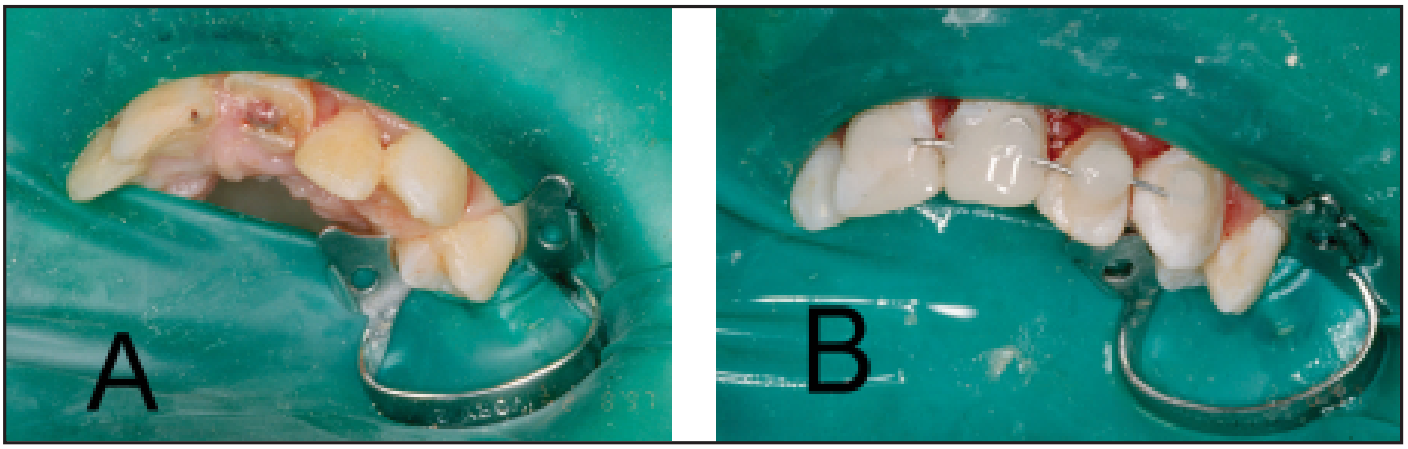

Figure 1. *Rubber dam cuff technique used during the emergency management of a trauma case with an uncomplicated crown fracture of the 11, a complicated crown-root fracture of the 21, and lateral luxation of the 22.*
A) Rubber dam immediately after placement - whilst there is some gingivae showing on the palatal and a gap between the dam and the palate, this set-up provides excellent conditions to manage the patient and the multiple injuries in this case.
B) Following repositioning of 22, pulp removal from 21, temporary composite restorations and rigid splinting of the teeth with wire and composite resin – all of which were done under rubber dam isolation.

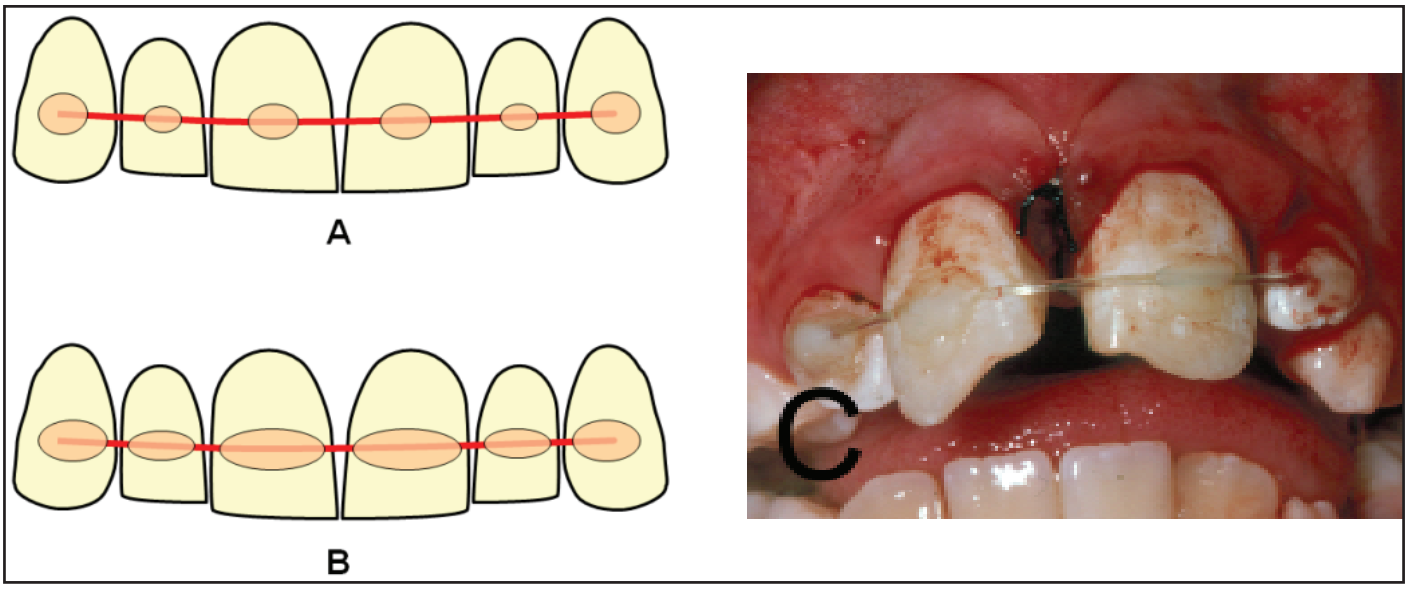

Figure 2. *A) Schematic diagram of a simple splint. The splinting material is placed away from the gingivae and the interproximal tooth surfaces are not covered by any splinting material. If a flexible splint is required, then use composite resin (shaded pink) to attach nylon fishing line (coloured red) to the labial surface of the teeth. This splint could be made rigid by substituting the nylon fishing line with stainless steel wire.*
B) The splint can also be made more rigid if desired by extending the composite resin further towards the mesial and distal edges of the labial tooth surfaces to cover more of the fishing line or wire.
C) An example of a flexible splint with nylon fishing line and composite to stabilise the two central incisors that had been avulsed and replanted. (Note: clinical examples of rigid splints with wire and composite are shown in Figures 1 and 3).

repositioned and stabilised as soon as possible to aid healing. If they are not returned to their normal positions, then healing will be impaired and may lead to fibrous/scar tissue formation, non-union of bone fractures and other complications.

The repositioning, replantation and stabilisation procedures should all be performed with appropriate general or local anaesthesia and under rubber dam isolation. Anaesthesia is required to ensure the patient is comfortable with no pain during the various procedures to reposition the teeth, bones and soft tissues, as well as during stabilisation and suturing (see below). Good pain control during treatment can also help to reduce the immediate post-operative discomfort.

Rubber dam isolation can be easily achieved using a "cuff technique" (*Figure 1*) across the entire anterior portion of the arch that has been traumatised (for example, from canine to canine, or from 1st premolar to 1st premolar) with clamps placed on teeth that were not affected by the trauma. The use of rubber dam has numerous advantages which include helping with overall patient management, protection of the airway and oesophagus, isolation to avoid unnecessary saliva and bacterial contamination of the affected teeth, ease of handling the displaced teeth and any loose fragments, improved handling and performance of the various materials used as well as improved visibility and access. Patients can also be more efficiently managed when rubber dam has been placed. In some cases, pulp treatment may be required (for example, pulpotomy, root canal treatment, etc) and rubber dam isolation is required for these procedures – hence, if the rubber dam is placed prior to repositioning the teeth, then all required emergency treatment can be readily performed.

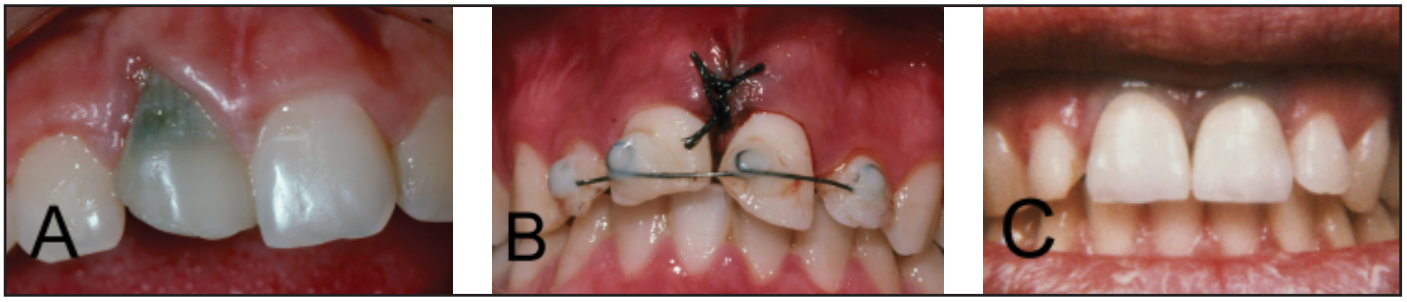

Figure 3. *A) An example of poor soft tissue management at the time of replantation of the lateral incisor following avulsion. No sutures were used to stabilise the gingivae, resulting in gingival recession, loss of attachment and loss of bone.*
B) In this different case, the two central incisors had been intruded such that the crowns were not visible, resulting in laceration of the gingivae in the midline. The laceration was sutured after the teeth were repositioned and stabilised with a rigid splint using wire and composite resin.
C) A five-year follow-up of the case in B) showing excellent soft tissue repair with a normal interdental papilla between the two central incisors.

Displaced teeth: Most teeth that have been displaced are relatively simple to reposition. They should then be stabilised by using a splint. Simple splints are preferred as they are easy to place, easy to remove, cheap, do not interfere with other treatment (such as suturing, root canal treatment, etc) and the patient is able to clean around them. Splints are usually applied to the labial surface of the injured tooth/teeth and one or two adjacent teeth on each side of the injured tooth/teeth to provide anchorage. Splints can be quickly made using composite resin and nylon fishing line (*Figure 2*) or stainless steel wire (*Figures 1 and 3B*). Other materials can also be used but they may not be as readily available, plus they may be more complicated to use and more expensive.

The material chosen for a splint depends on the type of splint required – that is, whether the splint needs to be rigid or flexible. A rigid splint is one that allows no, or minimal, movement of the teeth whereas a flexible splint allows normal physiological movement. Flexible splints are preferred for most luxation injuries since they allow "functional healing" of the PDL which reduces the chances of ankylosis and subsequent replacement resorption [22]. However, if there has been a root fracture or a fracture of the alveolar bone, then a more rigid splint is required in order to hold the fractured hard tissues together while healing [23], especially when the fracture is located in the coronal third of the root [24]. Rigid splints can be simply constructed using stainless steel wire on the labial while a flexible splint can be made with nylon fishing line (*Figures 1-3*). The rigidity of the splint can also be increased by extending the composite resin further across the labial surfaces of the teeth to cover more of the nylon fishing line or the wire (*Figure 2B*). The main purposes of a flexible splint are to hold the tooth in position while initial PDL healing occurs and to avoid the possibility of further displacement, inhalation or swallowing of the tooth.

Lateral luxation injuries typically result in the coronal portion of the tooth being displaced in a palatal direction with the apical part of the root being displaced labially [1,12]. There is also a fracture of the labial wall of the alveolar socket and this typically occurs at about the level of the junction of the apical third and middle third of the tooth root [1,25]. This creates a "ledge" of bone that then traps or locks the root apex labially. Hence these teeth need to be repositioned by first pushing downwards with a finger on the root apex to disengage it from the bone ledge, and then pushing the coronal part of the tooth towards the labial direction [25]. Typically, the dentist will feel the tooth "click" back into place. Since there is also a bone fracture associated with lateral luxation, this injury requires a rigid splint (*Figure 1*) for about six weeks in adults or about four weeks in children.

Extruded teeth are simple to reposition as they usually just need to be gently pushed back into the socket by using a finger applied to the incisal edge [26]. They should then be stabilised for 7-10 days with a flexible splint since there are usually no associated bone fractures. Some teeth may be difficult to reposition fully when a blood clot has formed in the apical part of the socket – hence, the sooner these teeth are repositioned, the easier it will be. If they cannot be fully seated, then subsequent orthodontic treatment may be required.

Intruded teeth should ideally be repositioned immediately although there is some debate and controversy about the management of this type of injury. Another recommendation is to wait and see if the tooth re-erupts by itself over the following few weeks. If this does not occur, then orthodontically extrude the tooth. Whilst this latter approach has been shown to be feasible, especially with incompletely developed teeth [27], there are some potential problems and disadvantages associated with it. Firstly, leaving the tooth in an intruded position is leaving the PDL and surrounding bone in an unfavourable situation as the pressure on these tissues may lead to necrosis, which in turn may lead to ankylosis and replacement resorption. Secondly, pulp necrosis occurs in virtually all fully developed teeth following intrusion as a result of crushing of the neurovascular bundle in the periapical region [19,20]. This in turn can lead to infection of the root canal system, especially if there is also a crown fracture or infractions that can allow bacteria to enter the tooth/pulp system. Then, the ideal conditions are established for external inflammatory root resorption to occur. Hence, ideally, immediate root canal treatment should be commenced in these teeth (see below) in order to prevent inflammatory resorption. This requires access to the root canal system which would normally be gained via a palatal access cavity cut with a high speed handpiece. This would be very difficult to perform in teeth that are extensively intruded and therefore repositioning and stabilisation with a splint would make this procedure far easier to perform. Similarly, pulp necrosis is extremely likely in incompletely developed teeth that are intruded and also have a crown fracture [19,20]–therefore these teeth should ideally have root canal treatment commenced immediately in order to prevent inflammatory resorption. Thirdly, spontaneous

eruption is unreliable when the tooth root is fully developed [28], and finally, if the tooth does not spontaneously re-erupt and orthodontic treatment becomes necessary, the patient will be subjected to a surgical procedure in order to attach orthodontic appliances to the tooth so it can be extruded. This extra treatment can be avoided simply by immediately repositioning the tooth as soon as possible after the injury.

Once repositioned, intruded teeth require a rigid splint (*Figure 3B*) as it is very likely that there will also be a fracture of the alveolar bone – this occurs because the tooth is essentially shaped like a wedge and can easily cause the labial wall of the socket to expand and fracture as the tooth is forced into the bone. Intrusion will always cause comminution (crushing) of the bone. Hence, rigid splinting for 4-6 weeks is preferred to allow optimum bone repair.

Avulsed teeth will need to be replanted back into the tooth socket [29]. The socket should first be checked to see if there is a blood clot present as this may prevent full seating of the tooth. If a blood clot is present, it can usually be easily removed with tweezers or a very fine suction tip – in all cases, be sure to avoid touching the socket wall as this may damage the PDL that remains on the socket wall. Gentle irrigation of the socket with saline can also help to remove a blood clot – if this is being done, then needles should be avoided as they may damage the PDL. Plastic syringes that include plastic tips are preferred – such as those used during surgical procedures for irrigation. Avulsed teeth may or may not have associated fractures of the alveolar wall. If a fracture is present, a rigid splint should be used but otherwise a flexible splint (Figure 2) is recommended for 7-10 days [29].

Fractures: Fractures also require repositioning and stabilisation of the fractured tissues. Crown fractures can be managed in a variety of ways using various dental restorative materials. The choice of material and technique will depend largely on the position and extent of the fracture. The pulp must be considered in all cases, even if it is not obviously exposed. Where no obvious exposure, the dentine should be covered in order to protect the pulp since the dentinal tubules provide direct pathways of entry for bacteria to reach the pulp if left open. This can be achieved with materials such as glass ionomer cements and composite resins. When the pulp is exposed, the stage of root development is the main factor that determines how the pulp should be managed. If the root is incompletely developed, then a conservative pulp treatment procedure should be utilised – such as a pulp cap, a partial pulpotomy, a cervical pulpotomy or a partial pulpectomy. The partial pulpotomy procedure advocated by Cvek is the treatment of choice due to the very high rate of favourable outcomes reported [17,18]. However, the choice of procedure will depend on the level of the crown fracture – for example, if the crown has fractured at gingival level, then only a cervical pulpotomy or a partial pulpectomy will be possible.

Fractures of a tooth root can present in many forms ranging from a single fracture to multiple fractures, in different parts of the tooth root (apical third, middle third, coronal third, sub-osseous, supra-osseous) and in different directions. In general, teeth with root fractures should be managed by repositioning the coronal fragment if it has been displaced and then stabilisation with a rigid splint [23,30,31]. There is some debate about how long these teeth should be splinted with some studies suggesting that only 3-4 weeks is necessary [23,31] while others recommend a longer period of 3-4 months to allow more time for hard tissue repair. If conditions are favourable, root-fractured teeth can repair internally by forming dentine along the root canal wall across the fracture line, and by cementum repair on the external surface of the root and perhaps extending into the fracture line giving the radiographic appearance of healing with hard tissue [31]. The dentine formation can only occur if the pulp is healthy and the odontoblasts adjacent to the fracture are stimulated to produce reactionary dentine along the root canal wall to cover the fracture line internally. It is believed that this dentine will be less likely to form if the coronal fragment is mobile and hence the longer splinting time is thought to create better conditions for pulp repair. Such repair is only likely to occur soon after the trauma and it is extremely unlikely to occur later.

It is very important that the pulp is not removed from teeth with root fractures as part of the emergency and short-term management. The pulp recovers in many teeth and may never need root canal treatment, even in cases where the fracture is close to the crestal bone level [23,24,30-33]. A number of studies have been published and summarized by Andreasen et al. [31] with varying rates of pulp necrosis after root fractures – ranging from as low as 4% to 55%. If the results of these studies are combined, a total of 1017 teeth had root fractures and only 274 (26.9%) developed pulp necrosis. Hence, the overall prognosis for pulp survival is very good following root fractures although there are many factors that affect individual cases. Pulp survival in root-fractured teeth is desirable since the pulp may produce reactionary dentine, as outlined above, which will help to stabilise the tooth.

Root canal treatment of root-fractured teeth should only be considered when there are very definite symptoms and/or signs of infection of the root canal system and these typically take some time to manifest. Such symptoms and signs include, but are not limited to, pain, swelling, increased mobility of the coronal fragment, a draining sinus, external inflammatory resorption of the coronal fragment, radiolucency between the coronal and apical fragments as well as adjacent to the fracture line, etc. In these cases, root canal treatment is only required for the coronal fragment – that is, only treat the canal to the fracture line. Calcium hydroxide can be used to ensure disinfection of the root canal and to encourage hard tissue healing at the fracture line (i.e. across the entrance to the coronal fragment's root canal). The canal can then be filled with gutta percha and cement, or with other materials such as Mineral Trioxide Aggregate (MTA) with various techniques [24,31,34].

Root fractures in the coronal third of the root benefit from longer splinting times up to 4 months [24] and these teeth should also be monitored to assess the pulp response and peri-radicular healing. However, in some cases of coronal third root fracture, it may be better to remove the coronal fragment and then commence root canal treatment immediately. This only applies to teeth where the fracture occurs just below the gingival margin but not below the level of the crestal bone, or where there is communication with the gingival crevice [31]. In these cases, the coronal fragment would have no bone and

no effective PDL to support it. These teeth will subsequently require a root canal filling and a comprehensive restoration using a post/core and full coverage crown but these can be provided when convenient rather than immediately. These teeth may also require orthodontic extrusion to facilitate their restoration [35]. In addition, periodontal surgery may be required to expose the margins to allow restoration of the tooth. Immediate management of complicated crown-root fractures is similar [36].

As above, bone fractures often occur with luxation injuries and should be managed in conjunction with the teeth. Bone fractures can also present as a fracture of the alveolar process with or without involving the tooth socket [1]. These injuries should not be confused with luxation injuries of the teeth but they may appear similar to lateral luxations or intrusions. However, the main distinguishing finding is that two or more teeth will move together as a segment rather than moving as individual teeth when one is tested for mobility [1]. All involved teeth will also be displaced in the same direction and to the same extent which is unlikely if they were separate luxation injuries. Alveolar process fractures are managed by repositioning the loose segment of bone which can be achieved by finger manipulation of the teeth to guide the bone back into position [37,38]. The teeth should be returned to their normal position in the arch which can be checked by assessing the occlusion. Once repositioned, a rigid splint can be placed on the teeth to hold the fractured bone segments together for optimum healing.

Fractures of the jaw (mandible and/or maxilla) can also occur when there is trauma to the teeth. These injuries are complex and will not be discussed in this review. Details can be obtained from appropriate oral surgery textbooks and journals. However, it is important to note that the teeth must not be neglected when there has been a jaw fracture since the blood supply to the dental pulps may have been affected by the injury and even by the treatment of the injury [38]. Teeth may also have injuries such as crown fractures, root fractures, luxation, etc so a thorough examination is required to identify and then manage these injuries in conjunction with the jaw fracture. Some teeth may also be involved in that the jaw fracture may involve the tooth socket. In this situation, the tooth should ideally be kept in place when the fracture is stabilised in order to reduce the chances of infection through an open socket if the tooth is removed. The tooth should also be carefully monitored for potential problems such as pulp necrosis and infection of the root canal system, root resorption, loss of attachment, gingival recession and other periodontal problems [38].

Strategy No. 3 - Soft tissue management

The third strategy to help reduce the consequences of trauma to the teeth is to know when soft tissue management is required. Attachment loss and gingival recession are two complications that can be largely avoided through good tissue management (*Figure 3A*). This requires that the soft tissues are repositioned back to their normal position and then stabilised in this position [39]. Stabilisation usually involves the use of sutures (*Figure 3B and 3C*) although other techniques or materials (such as cyanoacrylate) can sometimes be used.

Abrasions and contusions do not require much in the way of treatment. Abrasions should be thoroughly cleaned and disinfected but these are rare in the mouth. They are more likely to be on the external facial surface. Intra-oral contusions are also not common and they only require symptomatic relief if they are causing discomfort to the patient [39] – in which case, a non-steroidal anti-inflammatory drug would be indicated (such as ibuprofen).

Lacerations will require sutures to hold the cut surfaces in close proximity to each other in order to facilitate healing by primary intention [39]. Lacerations will often be associated with injuries where teeth are displaced – such as luxation, avulsion, alveolar bone fractures, alveolar process fractures, etc. The lacerated tissues require repositioning as do the teeth and bones; they then require stabilisation even if the laceration is only small, or short in length. The simple placement of a suture can avoid unsightly gingival recession as well as the subsequent loss of attachment and loss of crestal bone height (*Figure 3*). These can all lead to aesthetic problems as well as eventual loss of the tooth due to loss of PDL and bone support.

Many lacerations are obvious on examination but others require some probing or investigation in order to be revealed. In particular, luxations may be associated with "degloving-type" injuries of the gingivae on the palatal surface of upper incisors. In this case, the laceration is effectively occurring between the gingivae and the underlying bone and gingival fibres attached to the tooth. The displaced soft tissue may not be obvious on visual examination as it may be passively lying over the underlying bone. However, it is readily identified by periodontal probing and by testing the mobility of the soft tissue. Once identified as a degloving injury (i.e. a form of laceration), this tissue must be stabilised with sutures to ensure optimum positioning and conditions for healing. If it is not repositioned and stabilised, then loss of attachment, gingival recession, bone loss, etc. will occur over time.

Lacerations of the lip in patients who also have crown fractures should be carefully checked to determine whether any tooth fragments have penetrated the lip. Foreign objects may also penetrate the lips if the skin has also been lacerated [39]. In such cases, the lips should be radiographed with a film or sensor placed between the lip and teeth to check for tooth fragments and foreign objects. The exposure for such a radiograph should be 25% of the normal dose for intraoral radiographs. If any tooth fragments or foreign objects are present, these must be removed before the lacerations are sutured [39].

Strategy No. 4 – Immediate root canal treatment to prevent external inflammatory resorption in specific situations

The fourth strategy to help reduce the consequences of trauma to the teeth is to know when immediate pulp removal is required. As mentioned above, one of the complications or consequences of trauma to the teeth is external inflammatory root resorption (*Figure 4*). This type of resorption occurs when the root canal system has become infected AND where there has been either mechanical damage to the cementum during the trauma or loss of cementum through external surface resorption to the extent that the dentinal tubules have been exposed [40]. The bacteria in the root canal system can either move through the tubules and invoke the inflammatory

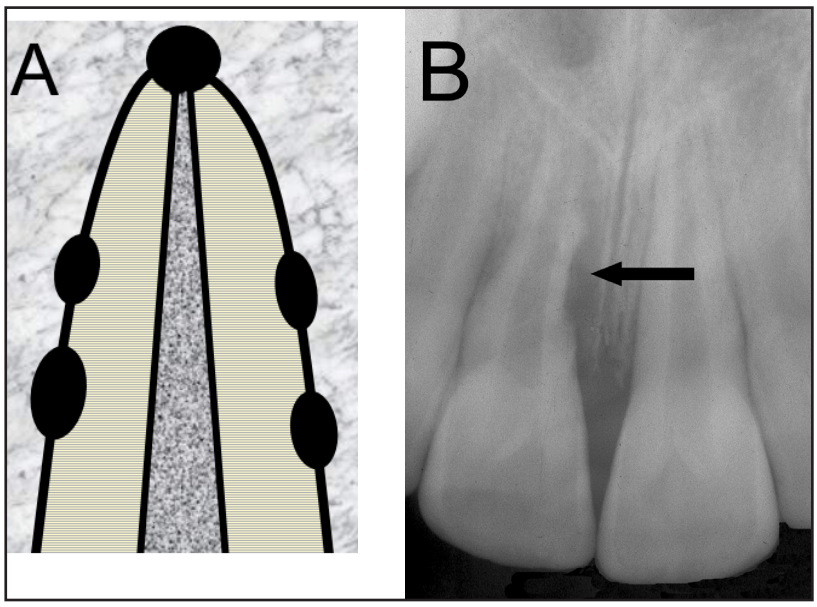

Figure 4. *A) Schematic diagram of external inflammatory resorption showing loss of tooth structure and loss of adjacent bone in the form of radiolucencies. External inflammatory resorption can occur on the lateral root surface or at the apex of the root.*
B) Radiograph showing external inflammatory resorption on the mesial surface (indicated by the arrow) of the root of the upper right central incisor – this was evident six months following avulsion and replantation of the tooth.

Table 5. *The injuries that are likely to result in pulp necrosis and infection of the root canal system, according to the stage of root development at the time of injury. Immediate root canal treatment following repositioning/replantation and splinting should be considered for teeth with these injuries in order to prevent the development of external inflammatory root resorption.*

Incompletely Developed Teeth	Fully Developed Teeth
• Intrusion with crown fracture • Avulsion with crown fracture	• Avulsion • Intrusion • Lateral Luxation with crown fracture • Extrusion with crown fracture

response in the PDL or the endotoxins produced by the bacteria may diffuse through the dentine to cause this. It may even be both the bacteria and their endotoxins. When there has been trauma to the PDL – such as a luxation injury – there will already be an inflammatory response in the PDL (because of the injury) so the bacteria and /or their endotoxins may only need to exacerbate this existing inflammation in order to initiate inflammatory resorption. Once the clastic cells are activated, the resorptive process will progress through the tooth root unless appropriate treatment is provided.

Studies have shown that it is possible to arrest external inflammatory resorption [40-42] and also to prevent it from occurring [41-46]. Since this type of resorption is dependent on having an infected root canal system, prevention or arrest of this resorption can be achieved through root canal treatment and by applying the same general principles that are used for such treatment [41-46]. As with all diseases, it is far better for the patient, and generally far more successful in outcome, to adopt a preventive approach rather than to wait for the disease to occur and then have to treat it.

When considering whether external inflammatory resorption is likely to occur to any particular tooth after trauma, the two key questions to answer are:

1. How likely is pulp necrosis and infection of the root canal system?

2. Has the external root surface been damaged or is external surface resorption likely to occur?

The literature can be used to determine which injuries are likely to have both of the above occur – these injuries are summarised in *Table 5*, according to the stage of root development at the time of injury. In general, pulp necrosis and infection are more likely with severe displacement injuries and these are also the most likely injuries to have damage to the root surface [19,20]. The presence of a crown fracture also makes pulp necrosis and infection more likely [20] because the fracture provides pathways for bacteria to enter the tooth and pulp system – such pathways could be a direct pulp exposure (i.e. a complicated crown fracture), exposed dentine tubules (uncomplicated crown fracture) or even through cracks when infractions occur.

Root surface damage increases as the degree of displacement increases – thus, concussion and subluxation rarely result in inflammatory resorption whereas intruded and avulsed teeth are very likely to have this resorption [47]. Extrusion and lateral luxation generally have less root surface damage and therefore less chance of inflammatory resorption unless there is also a crown fracture, as above. Root surface damage can also lead to external replacement resorption which is largely related to damage to the cementum and PDL. Unfortunately, external replacement resorption cannot be arrested once it has commenced and therefore it is important to minimise its occurrence where possible – however, this is not always possible since the damage usually occurs as part of the actual injury. External replacement resorption has a different radiographic appearance (*Figure 5*) and the tooth will give a different sound on percussion once this resorption is well established. Clinicians should be able to distinguish between external inflammatory and replacement resorption so appropriate treatment can be provided.

Immediate root canal treatment following repositioning/replantation and splinting should be considered for teeth with the injuries listed in *Table 5* in order to prevent the development of external inflammatory root resorption. This recommendation is based on numerous studies that have

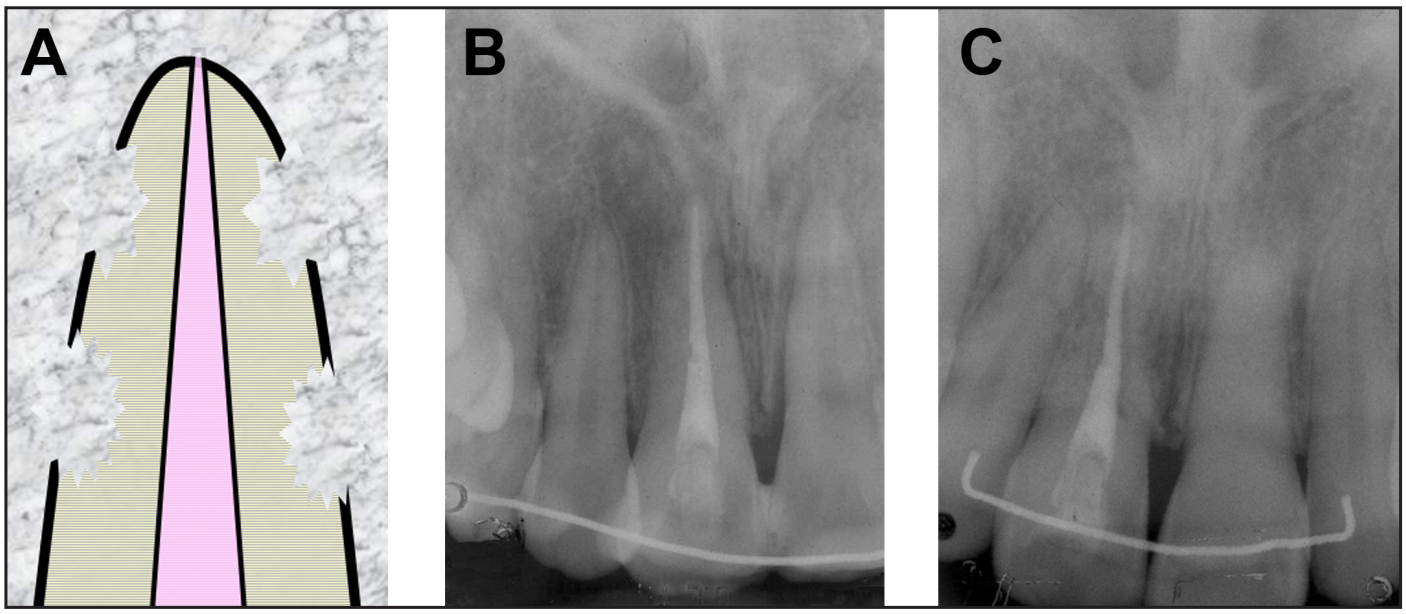

Figure 5. *A). Schematic diagram of external replacement resorption showing loss of tooth structure and its replacement by bone. B) Radiograph of an upper right central incisor that had been avulsed, replanted and splinted. The tooth had been out of the mouth and stored dry for three hours. The dentist performed extra-oral root canal treatment and placed a rigid splint. C) The tooth developed external replacement resorption which slowly progressed. This radiograph was taken four years after the injury and shows extensive resorption and ankylosis.*

investigated this type of resorption and the effects of root canal treatment with various intracanal medicaments. Some studies have also investigated the effects of systemic antibiotics on this type of resorption. These studies are summarised below.

Hammarström et al. [42] showed that immediate systemic use of antibiotics (penicillin and streptomycin) prevented external inflammatory resorption in a monkey study where teeth were avulsed, infected and replanted. However, if the antibiotics were given three weeks after the procedure, they had no effect as inflammatory resorption was already established and it continued despite the antibiotics. They also tested the intra-canal use of the same antibiotics and they reported that placing them immediately after replantation prevented inflammatory resorption. If they were placed in the root canal after three weeks, then they almost completely eliminated the resorption [42].

Sae-Lim et al. [44] used an "inflammatory resorption" model in dogs to compare the effects of systemic tetracycline, amoxicillin and a control without antibiotics. They reported that the tetracycline group had significantly less inflammatory resorption (33% of the root surface) than the control group (72%) but only slightly better than the amoxicillin group (43%) which was not significantly different to the control group. They concluded that since tetracycline has been shown to have anti-resorptive properties as they inhibit clastic cells [48] in addition to its anti-bacterial properties, it could be considered as an alternative to amoxicillin after avulsion injuries to prevent inflammatory resorption [44]. Tetracyclines have other properties which make them advantageous, especially when used within the tooth as intracanal medicaments as outlined below. These properties include their substantivity [49] and their bacteriostatic nature [50]. The latter is an advantage since, in the absence of bacterial cell lysis, antigenic by-products such as endotoxins are not released [50]. Tetracyclines also inhibit mammalian collagenases and therefore they help to prevent tissue breakdown [48].

In another study using a "replacement resorption" model in dogs and the same medication groups, Sae-Lim et al. [51] showed that there were significantly more teeth in the systemic tetracycline group with more than 50% of the root surface showing completely healed sites than in the systemic amoxicillin and control groups. In addition, there was more healing overall in the tetracycline group (35%) than in the amoxicillin (10.9%) and control groups (11.2%). Hence, the systemic use of tetracycline may also help to prevent external replacement resorption to a limited extent [51].

Corticosteroids have been investigated for their effects on inflammatory resorption because they are potent inhibitors of inflammation and they have a direct anti-resorptive action thorough their ability to inhibit clastic cells. Sae-Lim et al. [52] showed in their dog "replacement resorption" model that 85% of the root surface had complete healing when dexamethasone was applied topically before replantation of the extracted teeth whereas the systemic dexamethasone group had 67% of the root surfaces with healing. This latter group was similar to the control group (topical tissue culture medium) which had 69% of the root surface with healing.

Pierce and Lindskog [43] investigated the effects on inflammatory resorption of a commercially available corticosteroid/tetracycline compound known as Ledermix paste (Haupt Pharma GmbH, Wolfratshausen, Germany). In this study, they extracted monkey incisors, left them dry on the bench for an hour and then replanted them. The canals were also infected to create conditions to induce inflammatory resorption. One group of teeth had Ledermix paste placed in the root canals after three weeks and the other group were left empty. The Ledermix group showed no inflammatory resorption and no resorption in the PDL. In stark contrast, the other group had 89.3% of the root surface undergoing inflammatory resorption and another 8% of the root surface associated with inflammation in the PDL. The Ledermix group had 25.1% of the root surfaces with external surface resorption but this had not progressed to inflammatory resorption. There

was also 68% of the root with replacement resorption and/or ankylosis but this was a direct effect of the teeth being left dry on the bench for one hour prior to replantation since this would have resulted in necrosis of most of the PDL cells on the tooth root. Hence, this study showed that delayed placement of Ledermix paste prevented inflammatory resorption but it had no effect on replacement resorption [43]. Pierce et al. [53] then tested whether the anti-resorptive activity was due to the full paste (corticosteroid plus tetracycline) or just the tetracycline component (demeclocycline). Exposure of rat dentinoclasts to the demeclocycline was less effective than the entire paste, suggesting that the corticosteroid component was the most active anti-resorptive component. This is consistent with work by Suda et al. [54] who reported significant inhibition of osteoclasts when exposed to hydrocortisone.

The effect of corticosteroids has been subsequently confirmed by Chen et al. [46] in a dog study where they tested the immediate intracanal placement of Ledermix paste, triamcinolone alone, and demeclocycline alone. The control group had root canal fillings with gutta percha and cement. The teeth treated with Ledermix paste, triamcinolone and demeclocycline had statistically significantly more favourable healing (75.8%; 69.8%; 52.4%, respectively) and more remaining root structure (5.59; 5.48; 5.09 respectively on a scale of 1-6) than the positive control group (0; 1.15). There was no statistically significant difference between the Ledermix group and the triamcinolone group but there was a difference between these groups and the demeclocycline group. These results clearly indicate that the corticosteroid was the major anti-resorptive agent in Ledermix paste [46]. However, in this study, the canals were not infected so the true value of the tetracycline component is difficult to assess. It is expected that if the canals were infected, then the role of the antibiotic would be more important than in noninfected teeth since the antibiotic would inhibit any bacteria that enter the root canal system as well as potentially preventing any bacteria from entering the canal.

The timing of placement of the Ledermix paste is critical [45]. Inflammation begins as soon as the trauma has occurred to the tooth and therefore the sooner the anti-inflammatory agent is applied, the sooner it can begin to reduce this inflammatory reaction. In addition, if bacteria are prevented from entering the root canal system, then external inflammatory resorption is not likely to occur. Hence, if pulp necrosis is expected, then the immediate removal of the pulp and the placement of an appropriate medicament in the canal would seem advantageous and this has been shown to be the case by Bryson et al. [45]. In that study, the immediate placement of Ledermix paste was compared to the immediate placement of calcium hydroxide. The Ledermix group had significantly less resorption, significantly more healing and significantly more residual root mass than the calcium hydroxide group.

Calcium hydroxide has some useful properties in that it is a powerful anti-bacterial agent [9] but it has no direct anti-inflammatory action. Calcium hydroxide is a relatively toxic material which induces necrosis of cells that come into contact with it [55-57]. Hence, it can induce necrosis of both the resorbing cells and the reparative cells. This action on the reparative cells favours ankylosis and replacement resorption rather than healing of the PDL [55-57]. When placed in a root canal, calcium hydroxide will release the hydroxyl ion which diffuses through the dentinal tubules and cementum to reach the PDL [58]. If the cementum has been removed by the trauma or by surface resorption, then the diffusion of the hydroxyl ion will be faster and greater. The pH in the outer dentine can reach levels of approximately 8.0-9.5 [58] which is higher than the level at which attachment and growth of human PDL fibroblasts decreases (i.e. 7.8) [57]. Hence, calcium hydroxide can also affect PDL healing in this way and again the response favours ankylosis and replacement resorption [57].

When Ledermix paste is placed in the root canal of teeth, it releases the active components (triamcinolone and demeclocycline) [59]. These active components then diffuse through the dentine as well as through any lateral canals and the apical foramen to reach the peri-radicular tissues [59]. The major diffusion pathway is via the dentine tubules [59] and this diffusion increases if the cementum has been removed by the trauma or by surface resorption [60]. Hence, there is ready availability of the active components to the tissues where they can act to prevent inflammatory resorption. The tetracycline (antibiotic) works within the dentine tubules by inhibiting bacterial growth whilst the triamcinolone (corticosteroid) works within the peri-radicular tissues by reducing inflammation and inhibiting clastic cells. Ledermix has been reported to maintain the release and diffusion process for about six weeks in fully developed teeth and for about four weeks in immature teeth [59]. After these times, the amount of each drug being released is lower than the effective therapeutic levels. Hence, Ledermix paste used as an intracanal medicament needs to be removed and replaced after these time intervals in order to continue acting effectively.

In experimental studies, PDL healing was complete after eight weeks following simulated avulsion injuries [61]. However, the healing response is also dependent on other factors and therefore it may be delayed [61]. Factors that delay healing include the presence of infection [61], physical damage to the root and bone, contusion, rupture of blood vessels, necrosis of damaged tissue, the presence of foreign bodies [62] and the effects of concurrent distant wound healing associated with other injuries [62,63]. Many or all of these factors are likely to be present following trauma to teeth. Hence, a cautious approach of allowing at least three months for healing should be considered following most luxation injuries. Ideally, the root canal system needs to be medicated for at least this time and preferably for longer periods as the true healing response is difficult to assess radiographically during the first 3-6 months [40]. Ledermix paste is recommended for the first three months – this implies two dressings of six weeks each for mature teeth, or three dressings for four weeks each in incompletely developed teeth. After three months, a periapical radiograph should be taken to assess whether there is any external inflammatory resorption occurring [40]. If resorption is evident, then continue using Ledermix paste for a further three months to try and stop the resorption. However, in almost all cases, there will be no inflammatory resorption evident so calcium hydroxide can be introduced into the medicament as a 50:50 mixture with Ledermix

Table 6. *Recommended preventive treatment protocol for teeth with the injuries listed in Table 5 to prevent external inflammatory root resorption.*
NOTES: 1) The treatment must be commenced as soon as the tooth has been replanted/repositioned and stabilised with splint;
2) Check the patient's age, weight, allergies etc. to determine appropriate systemic antibiotic doses;
3) Alternative systemic antibiotics are penicillin and amoxicillin;
4) CS-AB = corticosteroid/antibiotic;
5) Working length and canal preparation can be deferred until the second treatment appointment.

Incompletely Developed Teeth
• Systemic antibiotics - start IMMEDIATELY - Tetracycline preferred - e.g. doxycycline 100 mg - 2 tablets on the 1st day, and then 1 tablet daily for 1 week • IMMEDIATELY after replantation/repositioning/splinting - Remove the pulp, clean the root canal - if time: measure, file, irrigate, dry - Place a CS-AB paste dressing - e.g. Ledermix paste • After 4 weeks - complete canal preparation, place a new CS-AB paste dressing • After another 4 weeks - place a new CS-AB paste dressing • After another 4 weeks - take a periapical radiograph - If no inflammatory resorption evident – place a dressing using a 50:50 mixture of CS-AB & $Ca(OH)_2$ • After 2-3 months - take a periapical radiograph - If no inflammatory resorption evident – place a $Ca(OH)_2$ dressing – to induce formation of an apical hard tissue barrier • Change the $Ca(OH)_2$ dressing every 3 months until hard tissue repair (e.g. apexification) is evident. Periapical radiograph every 6 months to ensure healing • Place the root canal filling using gutta percha and cement • Perform internal bleaching if required and then restore the access cavity • Arrange to review after 6 months and then annually for at least 5 years
Fully Developed Teeth
• Systemic antibiotics - start IMMEDIATELY - Tetracycline preferred - e.g. doxycycline 100 mg - 2 tablets on the 1st day, and then 1 tablet daily for 1 week • IMMEDIATELY after replantation/repositioning/splinting - Remove the pulp, clean the root canal - if time: measure, file, irrigate, dry - Place a CS-AB paste dressing - e.g. Ledermix paste • After 6 weeks - complete canal preparation, place a new CS-AB paste dressing • After another 6 weeks - take a periapical radiograph - If no inflammatory resorption evident – place a dressing using a 50:50 mixture of CS-AB & $Ca(OH)_2$ • After 2-3 months - take a periapical radiograph - If no inflammatory resorption evident – place the root canal filling using gutta percha and cement • Perform internal bleaching if required and then restore the access cavity • Arrange to review after 6 months and then annually for at least 5 years.

paste. The use of this combination reduces the toxicity of the calcium hydroxide [64] and therefore there is less chance of ankylosis and replacement resorption occurring. In addition, this combination of materials increases the anti-bacterial spectrum compared to Ledermix paste used alone [65,66], and the hard tissue healing effects of the calcium hydroxide can begin to work. There is a slight reduction in pH levels of approximately 0.3 pH units when the medicaments are combined [67] and each of the three main components of the mixture (triamcinolone, demeclocycline, calcium hydroxide) remain active [67]. The calcium hydroxide also has the added effect of slowing down the release and diffusion of the Ledermix paste components which means that they remain in the canal for a longer period of time – up to three months maximum [64]. Hence, a period of 2-3 months with the 50:50 mixture of Ledermix paste and calcium hydroxide can be used to encourage further healing prior to completing the root canal filling. If further hard tissue formation is required (e.g. incompletely developed teeth requiring apexification), then calcium hydroxide can be used alone after the 50:50 dressing period. In these cases, the calcium hydroxide is ideally replaced every three months until the tooth is ready for the root canal filling (e.g. once an apical hard tissue barrier has formed) [68]. The overall treatment time is about 12 months on average for incompletely developed teeth when the extra calcium hydroxide dressings are needed, and typically only 5-6 months for mature teeth. These time periods also allow time to assess whether external replacement resorption and ankylosis are occurring – if so, the overall prognosis of the tooth needs to be determined and an alternative treatment plan (such as extraction at an appropriate time) may be necessary.

The recommended approach for preventing external inflammatory resorption is summarised in *Table 6*. This approach may also help to reduce the amount of replacement resorption to a small extent [45,51] but this type of resorption is dependent on the amount and type of damage to the tooth root and PDL during the actual injury as well as during the repositioning or replantation procedures. This preventive approach to avoid inflammatory resorption has been used for many years by the authors. A review of 60 teeth in 52 patients managed by this approach showed that none of the teeth developed external inflammatory root resorption [41]. In these teeth, inflammatory resorption would have been highly likely if no treatment had been provided due to the type of injury sustained.

Strategy No. 5 - Follow-up of all traumatised teeth

It is essential to review and follow-up all traumatised teeth in order to identify and manage any adverse consequences as soon as they occur [12]. Most problems can be more effectively managed if identified early – for example, if external inflammatory resorption occurs in a tooth where the above preventive approach has not been followed, there

will be less tooth structure loss if it is identified and managed early rather than later. Treatment can be initiated to arrest the resorption and then to encourage repair of the cementum, PDL and bone [40,42]. This is more likely to be successful if the resorption is not too advanced, whereas very advanced cases are less likely to recover.

Some problems may be prevented through early identification of symptoms or signs of unfavourable tissue responses – for example, early identification and treatment of pulp necrosis and infection of the root canal system will minimise the loss of bone in the periapical region, reduce the chances of other pathosis developing (such as extra-radicular infections, periapical true cysts, etc) and generally have a higher chance of healing of the periapical tissues.

There are some consequences of trauma to the teeth that cannot be prevented or managed in a way that retains the tooth in a stable, functional and aesthetic manner. For example, external replacement resorption and ankylosis are largely a result of damage to the tooth root and PDL during the actual injury (i.e. avulsion, intrusion, lateral luxation, etc) and sometimes during the replantation or repositioning of the tooth, especially if performed by the patient, a bystander, or other person with no dental training. In these cases, the damage has been done before the patient sees the dentist. At this point in time, research has not revealed any effective management that will prevent or arrest external replacement resorption. The studies mentioned above [45,51] have shown some slight reduction in the amount of replacement resorption occurring in teeth treated with corticosteroids and tetracycline antibiotics (used both systemically and as intracanal medicaments) but it is believed to be only a minimal and temporary effect. Once external replacement resorption has commenced, it will usually continue and result in loss of the tooth.

Some patients do not seek immediate or even early dental treatment after having trauma to their teeth. In a study based in a large Australian rural centre [4], approximately one third of the patients presented to a dental clinic within 24 hours of the injury, one third presented within one week and the remaining third presented over periods ranging from one week up to 52 weeks. Delays in seeking treatment mean that the ideal treatment is not always possible to provide and this can lead to the development of any of the unfavourable tissue responses [69] outlined in *Tables 1-3*. Once most problems have developed, they are usually more difficult to treat. Follow-up of patients who have delayed seeking initial treatment is therefore even more essential than for those patients who had ideal early or immediate management of their injuries.

Regular follow-up of patients is important even when there are obvious unfavourable responses that cannot be managed conservatively since these will typically lead to loss of the traumatised tooth or teeth. For example, external replacement resorption and ankylosis, once present, will progress to the point where the tooth will need to be extracted and then replaced with some form of prosthesis since trauma usually occurs to upper anterior teeth and most patients will be concerned about the aesthetics following loss of the tooth. A prosthesis will also be required for other reasons such as function and arch stability. In these cases, the timing of the extraction can be critical and will need considerable thought and planning. Many factors will be involved and the ultimate decision on when to extract may be determined by the type of prosthesis chosen, patient age, patient activities (e.g. sport participation, etc), amount of bone present, finances, etc. In these cases it is critical that the rate of replacement resorption is monitored by regular clinical reviews and radiographs to determine when the tooth should be extracted.

Conclusions

There are many different potential responses of the pulp, peri-radicular and soft tissues following trauma to a tooth. The responses for each traumatised tooth are dependent on many factors, including the type and extent of the injury, the stage of root development and whether there has been more than one injury to the same tooth. The responses of the different tissues are inter-related and dependent on each other. All of these factors imply that there are many potential consequences of trauma to the teeth. It is imperative that dentists have a thorough understanding of these tissue responses so the appropriate treatment can be provided to minimise the consequences of trauma to the teeth. The main strategies to reduce the consequences include performing a thorough examination and accurate diagnosis, repositioning and stabilisation of the teeth and bones, careful soft tissue management, immediate root canal treatment in specific situations to prevent external inflammatory resorption, and the follow-up of all traumatised teeth to identify and manage any adverse consequences as soon as possible.

References

1. Glendor U, Marcenes W, Andreasen JO. Classification: epidemiology and etiology. In: Andreasen JO, Andreasen FM, Andersson L (Editors) Textbook and color atlas of traumatic injuries to the teeth. (4th Edn.) Oxford UK: Blackwell. 2007; pp. 217–254.
2. Andreasen JO, Ravn JJ. Epidemiology of traumatic dental injuries to primary and permanent teeth in a Danish population sample. *International Journal of Oral Surgery*. 1972; **1**: 235-239.
3. Glendor U, Halling A, Andersson L, Eilert-Petersson E. Incidence of traumatic tooth injuries in children and adolescents in county of Västmanland, Sweden. *Swedish Dental Journal*. 1996; **20**: 15-28.
4. Lam R, Abbott PV, Lloyd C, Lloyd C, Kruger E, et al. Dental trauma in an Australian rural centre. *Dental Traumatology*. 2008; **24**: 663-670.
5. Stockwell AJ. Incidence of trauma in the Western Australian School Dental Service. *Community Dentistry and Oral Epidemiology*. 1988; **16**: 294-298.
6. Davis G, Knott S. Dental trauma in Australia. *Australian Dental Journal*. 1984; **29**: 217–221.
7. Liew VP, Daly CG. Anterior dental trauma treated after hours in Newcastle, Australia. *Community Dentistry and Oral Epidemiology*. 1986; **14**: 362-366.
8. Andreasen JO, Vinding TR, Ahrensburg SS. Etiology and predictors for healing complications in the permanent dentition after dental trauma. A review. *Endodontic Topics*. 2006; **14**: 20-27.
9. Cvek M. Endodontic management and the use of calcium hydroxide in traumatized permanent teeth. In: Andreasen JO,

Andreasen FM, Andersson L (Editors) Textbook and color atlas of traumatic injuries to the teeth, 4th Edn. Oxford UK: Blackwell. 2007; pp. 598-657.

10. Lauridsen E, Hermann NV, Gerds TA, Kreiborg S, Andreasen JO. Pattern of traumatic dental injuries in the permanent dentition among children, adolescents, and adults. *Dental Traumatology*. 2012; **28**: 358-63.

11. Andreasen FM, Andreasen JO, Tsukiboshi M. Examination and diagnosis of dental injuries. In: Andreasen JO, Andreasen FM, Andersson L (Editors) Textbook and color atlas of traumatic injuries to the teeth. (4th edn.) Oxford UK: Blackwell. 2007; pp. 255-279.

12. Andreasen JO, Bakland LK, Flores MT, Andreasen FM, Andersson L. Traumatic dental injuries – A manual. (3rd Edn.) West Sussex, UK: Wiley-Blackwell. 2011; pp. 18-21.

13. Andreasen FM, Andreasen JO. Diagnosis of luxation injuries. The importance of standardized clinical, radiographic and photographic techniques in clinical investigations. *Endodontics & Dental Traumatology*. 1985; **1**: 160-169.

14. Andreasen FM, Yu Z, Thomsen BL. The relationship between pulpal dimensions and the development of pulp necrosis in the permanent dentition. *Endodontics & Dental Traumatology*. 1986; **2**: 90-98.

15. Cvek M. Prognosis of luxated non-vital maxillary incisors treated with calcium hydroxide and filled with gutta percha. *Endodontics & Dental Traumatology*. 1992; **8**: 45-55.

16. Andreasen FM, Vestergaard-Pedersen B. Prognosis of luxated permanent teeth – the development of pulp necrosis. *Endodontics & dental traumatology*. 1985; **1**: 207-220.

17. Cvek M. A clinical report on partial pulpotomy and capping with calcium hydroxide in permanent incisors with complicated crown fracture. *Journal of Endodontics*. 1978; **4**: 232-237.

18. Cvek M. Partial pulpotomy in crown-fractured incisors – results 3 to 15 years after treatment. *Acta Stomatologica Croatia*. 1993; **27**: 167-173.

19. Andreasen FM. Pulpal healing after luxation injuries and root fracture in the permanent dentition. *Endodontics & Dental Traumatology*. 1989; **5**: 111-131.

20. Andreasen JO, Andreasen FM. Crown fractures. In: Andreasen JO, Andreasen FM (Editors) Essentials of traumatic injuries to the teeth. (2nd Edn.) Copenhagen: Munksgaard. 2000; pp. 21-46.

21. Dental Trauma Guide. Accessed at: http://www.dentaltraumaguide.org/.

22. Oikarinen K. Functional fixation for traumatically luxated teeth. *Endodontics & Dental Traumatology*. 1987; **3**: 224-228.

23. Andreasen JO, Andreasen FM, Mèjare I, Cvek M. Healing of 400 intra-alveolar root fractures. 2. Effect of treatment factors such as treatment delay, repositioning, splinting type period and antibiotics. *Dental Traumatology*. 2004; **20**: 203-211.

24. Cvek M, Mèjare I, Andreasen JO. Healing and prognosis of teeth with intra-alveolar fractures involving the cervical part of the root. *Dental Traumatology*. 2002; **18**: 57-65.

25. Andreasen JO, Bakland LK, Flores MT, Andreasen FM, Andersson L. Traumatic dental injuries – A manual. (3rd Edn.) West Sussex, UK: Wiley-Blackwell. 2011; pp. 44-45.

26. Andreasen JO, Bakland LK, Flores MT, Andreasen FM, Andersson L. Traumatic dental injuries – A manual. (3rd Edn.) West Sussex, UK: Wiley-Blackwell. 2011; pp. 42-43.

27. Andreasen JO, Bakland LF, Andreasen FM. Traumatic intrusion of permanent teeth. Part 3. A clinical study of the effect of treatment variables such as treatment delay, method of repositioning, type of splint, length of splinting and antibiotics on 140 teeth. *Dental Traumatology*. 2006; **22**: 99-111.

28. Andreasen JO, Bakland LK, Flores MT, Andreasen FM, Andersson L. Traumatic dental injuries – A manual. (3rd Edn.) West Sussex, UK: Wiley-Blackwell. 2011; pp. 46-47.

29. Andreasen JO, Bakland LK, Flores MT, Andreasen FM, Andersson L. Traumatic dental injuries – A manual. (3rd Edn.) West Sussex, UK: Wiley-Blackwell. 2011; pp. 48-53.

30. Andreasen JO, Andreasen FM, Mèjare I, Cvek M. Healing of 400 intra-alveolar root fractures. 1. Effect of pre-injury and injury factors such as sex, age, stage of root development, fracture type, location of fracture and severity of dislocation. *Dental Traumatology*. 2004; **20**: 192-202.

31. Andreasen FM, Andreasen JO, Cvek M. Root fractures. In: Andreasen JO, Andreasen FM, Andersson L, Ed's. Textbook and color atlas of traumatic injuries to the teeth. (4th Edn.) Oxford, UK: Blackwell. 2007; pp. 337-371.

32. Andreasen JO, Hjörting-Hansen E. Intra-alveolar root fractures: radiographic and histologic study of 50 cases. *Journal of Oral Surgery*. 1965; **25**: 414-426.

33. Andreasen FM, Andreasen JO, Bayer T. Prognosis of root fractured permanent incisors – prediction of healing modalities. *Endodontics & Dental Traumatology*. 1989; **5**: 11-22.

34. Cvek M, Mèjare I, Andreasen JO. Conservative endodontic treatment of teeth fractured in the middle or apical part of the root. *Dental Traumatology*. 2004; **20**: 262-269.

35. Heithersay GS. Combined endodontic-orthodontic treatment of transverse root fractures in the region of the alveolar crest. *Oral Surgery, Oral Medicine, Oral Pathology*. 1973; **36**: 404-415.

36. Andreasen JO, Andreasen FM, Tsukiboshi M. Crown-root fractures. In: Andreasen JO, Andreasen FM, Andersson L (Editors) Textbook and color atlas of traumatic injuries to the teeth. (4th Edn.) Oxford UK: Blackwell. 2007; pp. 314-336.

37. Andreasen JO, Bakland LK, Flores MT, Andreasen FM, Andersson L. Traumatic dental injuries – A manual. (3rd Edn.) West Sussex, UK: Wiley-Blackwell. 2011; pp. 36-37.

38. Andreasen JO. Injuries to the supporting bone. In: Andreasen JO, Andreasen FM, Andersson L (Editors) Textbook and color atlas of traumatic injuries to the teeth. (4th Edn.) Oxford UK: Blackwell. 2007; pp. 489-515.

39. Andreasen JO, Bakland LK, Flores MT, Andreasen FM, Andersson L. Traumatic dental injuries – A manual. (3rd Edn.) West Sussex, UK: Wiley-Blackwell. 2011; pp. 58-61.

40. Abbott PV. Treatment of external apical inflammatory root resorption. *Australian Endodontic Newsletter*. 1992; **17**: 22-26.

41. Abbott PV. Treatment of external inflammatory root resorption with Ledermix paste. *Australian Endodontic Journal*. 1999; **25**:104-105.

42. Hammarström L, Blömlof L, Feiglin B, Andersson L, Lindskog S. Replantation of teeth and antibiotic treatment. *Endodontics & Dental Traumatology*. 1986; **2**: 51-57.

43. Pierce A, Lindskog S. The effect of an antibiotic/corticosteroid paste on inflammatory root resorption in vivo. *Oral Surgery, Oral Medicine, Oral Pathology*. 1987; **64**: 216-20.

44. Sae-Lim V, Wang CY, Trope M. Effect of systemic tetracycline and amoxicillin on inflammatory root resorption of replanted dogs' teeth. *Endodontics & Dental Traumatology*. 1998; **14**: 216-220.

45. Bryson E, Levin L, Banchs F, Abbott P, Trope M. Effect of immediate intracanal placement of Ledermix paste on healing of replanted dog teeth after extended dry times. *Dental Traumatology*. 2002; **18**: 316-321.

46. Chen H, Teixeira FB, Ritter AL, Levin L, Trope M. The effect of intracanal anti-inflammatory medicaments on external root resorption of replanted dog teeth after extended extra-oral dry time. *Dental Traumatology*. 2008; **24**: 74-78.

47. Andreasen JO, Bakland LK, Flores MT, Andreasen FM, Andersson L. Traumatic dental injuries – A manual. (3rd Edn.) West Sussex, UK: Wiley-Blackwell. 2011; pp. 70-73.

48. Vernillo AT, Ramamurthy NS, Golub LM, Rifkin BR. Non-antimicrobial action of tetracyclines. *Current Opinions in Periodontology*. 1994; **2**: 111-118.

49. Torabinejad M, Khademi AA, Babagoli J, Cho Y, Johnson WB, et al. A new solution for the removal of the smear layer. Journal of Endodontics. 2003; 29: 170-175.

50. Barkhordar RA, Watanabe LG, Marshall GW, Hussain MZ. Removal of intracanal smear by doxycycline in vitro. *Oral Surgery, Oral Medicine, Oral Pathology, Oral Radiology and Endodontics*. 1997; **84**: 420-423.

51. Sae-Lim V, Wang CY, Choi GW, Trope M. Effect of systemic tetracycline on resorption of dried replanted dogs' teeth. *Endodontics & Dental Traumatology*. 1998; **14**: 127-132.

52. Sae-Lim V, Metzger Z, Trope M. Local dexamethasone improves healing of replanted dogs' teeth. *Endodontics & Dental Traumatology*. 1998; **14**: 232-236.

53. Pierce A, Heithersay G, Lindskog S. Evidence for direct inhibition of dentinoclasts by a corticosteroid/antibiotic paste. *Endodontics & Dental Traumatology*. 1988; **4**: 44-45.

54. Suda T, Testa NG, Allen TD, Onions D, Jarrett O. Effect of hydrocortisone on osteoclasts generated in cat bone marrow cultures. *Calcified Tissue International*. 1983; **35**: 82-86.

55. Lengheden A, Blömlof L, Lindskog S. Effect of immediate calcium hydroxide treatment on periodontal healing in contaminated replanted teeth. *Scandinavian Journal of Dental Research*. 1991; **99**: 139-146.

56. Lengheden A, Blömlof L, Lindskog S. Effect of delayed calcium hydroxide treatment on periodontal healing in contaminated replanted teeth. *Scandinavian Journal of Dental Research*. 1991; **99**: 147-153.

57. Lengheden A. Influence of pH and calcium on growth and attachment of human fibroblasts in vitro. *Scandinavian Journal of Dental Research*. 1994; **102**: 130-136.

58. Nerwich A, Figdor D, Messer HH. pH changes in root dentin over a 4-week period following root canal dressing with calcium hydroxide. *Journal of Endodontics*. 1993; **19**: 302-306.

59. Abbott PV, Heithersay GS, Hume WR. The release and diffusion through human tooth roots in vitro of corticosteroid and tetracycline trace molecules from Ledermix paste. *Endodontics & Dental Traumatology*. 1988; **4**: 55-62.

60. Abbott PV, Hume WR, Heithersay GS. Barriers to diffusion of Ledermix paste in radicular dentine. *Endodontics & Dental Traumatology*. 1989; **5**: 98-104.

61. Andreasen JO, Løvschall H (2007) Response of oral tissues to trauma. In: Andreasen JO, Andreasen FM, Andersson L (Editors). Textbook and color atlas of traumatic injuries to the teeth. (4th Edn.) Oxford UK: Blackwell. 2007; pp. 62-113.

62. Gottrup F, Storgård Jensen S, Andreasen JO. Wound healing subsequent to injury. In: Andreasen JO, Andreasen FM, Andersson L (Editors). Textbook and color atlas of traumatic injuries to the teeth. (4th Edn.) Oxford UK: Blackwell. 2007; pp. 1-61.

63. Zederfeld TB. Factors influencing wound healing. In: Viidik A, Vuust S (Editors) Biology of collagen. London, UK: Academic Press. 1980; pp. 347-352.

64. Abbott PV, Hume WR, Heithersay GS. The effect of combining Ledermix and calcium hydroxide pastes on the diffusion of corticosteroid and tetracycline through human tooth roots in vitro. *Endodontics & Dental Traumatology*. 1989; **5**: 188-192.

65. Athanassiadis B, Abbott PV, George N, Walsh LJ. An in vitro study of the antimicrobial activity of some endodontic medicaments and their bases using an agar well diffusion assay. *Australian Dental Journal*. 2009; **54**: 141-156.

66. Athanassiadis B, Abbott PV, Walsh LJ, George N. An in vitro study of the anti-microbial activity of some endodontic medicaments against Enterococcus faecalis biofilms *Australian Dental Journal*. 2010; **55**: 150-155.

67. Taylor MA, Hume WR, Heithersay GS. Some effects of Ledermix paste and Pulpdent paste on mouse fibroblasts and on bacteria in vitro. *Endodontics & Dental Traumatology*. 1989; **5**: 266-273.

68. Abbott PV. Apexification with calcium hydroxide - When should the dressing be changed? The case for regular dressing changes. *Australian Endodontic Journal*. 1998; **24**: 27-32.

69. Andreasen JO, Andreasen FM, Skeie A, Hjörting-Hansen E, Schwartz O. Effect of treatment delay upon pulp and periodontal healing of traumatic dental injuries a review article. *Dental Traumatology*. 2002; **18**: 116-128.