

Panoramic Radiography for Screening Postmenopausal Osteoporosis in India: A Pilot Study

Pankaj R Bodade¹, Rajendra N Mody²

¹MDS, BDS. Associate Professor, Department of Oral Medicine and Radiology, Vidarbha Youth Welfare Society's Dental College and Hospital, Amravati, Maharashtra, India. ²MDS, BDS. Professor and Head of Department of Oral Medicine and Radiology, Hitkarini Dental College and Hospital, Jabalpur, India.

Abstract

Aim: The overall aim of this pilot study was to establish the role of dental practitioners in identifying patients at risk of osteoporosis from panoramic radiographs.

Methods: The pilot study evaluated 32 randomly selected postmenopausal women with no known secondary cause of bone loss. A panoramic radiograph of each patient was taken and qualitative and quantitative radiomorphometric indices were determined. Bone mineral densities of the mandible and lumbar vertebrae were measured by dual energy x-ray absorptiometry. Using World Health Organization criteria, patients were divided into normal, osteopenic and osteoporotic categories. The relationship of qualitative and quantitative indices with bone mineral densities of the mandible and lumbar area was analysed statistically.

Results: Significant positive correlation (Pearson coefficient) was observed between bone mineral densities of the mandible and bone mineral densities of lumbar vertebrae. There was significant ($P < 0.05$) association between the mandibular cortical index (MCI) and osteoporosis (chi-square test), incidence of osteoporosis increased from group C1 to C2 to C3. Strong positive correlation (Pearson coefficient) was observed between all quantitative indices and bone mineral densities of lumbar vertebrae. Intra-observer and inter-observer reproducibility for the quantitative indices was poor (paired and unpaired *t*-tests, respectively). However, it was excellent for the mandibular cortical index (kappa coefficient).

Conclusions: The mandibular cortical index, a qualitative index based on morphological changes in the inferior cortex observed on panoramic radiograph, is useful tool for the screening of postmenopausal osteoporotic patients. Quantitative indices (mental index, inferior and superior panoramic mandibular indices, antegonion index and gonion index), although well correlated with skeletal bone loss, were not useful because of their poor reproducibility. A study with a larger sample is needed to confirm the results from this pilot.

Key Words: Postmenopausal, Osteoporosis, Panoramic, Absorptiometry

Introduction

Review of literature

Osteoporosis is the most common metabolic bone disease of the elderly, characterised by low bone mass and micro-architectural deterioration of the osseous scaffold that results in bone fragility and increased susceptibility to fracture [1]. Sequelae of osteoporotic fractures are acute and chronic disabling pain, vertebral deformities, postural slumping and loss of height. Most commonly affected bones are vertebrae, hip bones, wrist bones, humerus and tibia [2]. Since the earliest suggestion of an association between osteoporosis and mandibular bone loss made by Groen *et al.* (1960)

[3], a number of studies have attempted to predict skeletal osteoporosis from dental radiographs by studying various parameters such as mandibular cortical porosity, alveolar bone height, architecture of trabecular bone, buccal cortical width, inferior cortical thickness and radiographic density.

In previous studies, various indices derived from panoramic radiographs have been used to predict the skeletal osteoporosis. However, none of the studies evaluated all the indices simultaneously and compared their relative usefulness. Few studies [4] have tried to correlate these indices with mandibular bone mineral density measured by dual energy x-ray absorptiometry (DXA), which is the current gold standard for predicting fracture risk. Even

Corresponding author: Dr Pankaj R Bodade, Flat no. 202, Ratan Heritage Apartment, Plot no. 34, Revati Nagar, Besa, Nagpur-440034, Maharashtra, India; e-mail: drpankaj777@hotmail.com

though osteoporosis is highly prevalent in India [5], no study has been reported establishing the role of dental radiographs in its detection. Very few studies have used a common scale to compare bone mineral densities of the mandible with other commonly affected bones.

Aims

Taking these facts into consideration, this pilot study in postmenopausal patients was designed with the overall aim of establishing the role of dental practitioners in identifying from panoramic radiographs those patients at risk of osteoporosis. It had following objectives:

1. To evaluate the relationship of mandibular bone mineral density (MBMD) with that of the lumbar vertebrae (L1-L4) measured by DXA.
2. To evaluate the relationship of radiomorphometric (qualitative and quantitative) indices derived from panoramic radiographs with bone mineral densities of the lumbar vertebrae (L1-L4) measured by DXA.
3. To evaluate the intra-observer and inter-observer reproducibility of qualitative and quantitative indices.

Methods

Females in natural menopause (defined as occurring after 12 months of amenorrhoea without any obvious pathologic cause) were randomly selected from the Department of Oral Medicine and Radiology of the Government Dental College and Hospital, Nagpur, Maharashtra, India. Every fifth female patient fulfilling the above criteria who came for dental evaluation to the Department of Oral Medicine and Radiology during the two-month study period was selected. After detailed history, some patients were excluded based on the following criteria:

1. A history of hyperparathyroidism, hypo/hyperthyroidism, diabetes mellitus, chronic renal failure, hypogonadism, pituitary tumours, Addison's disease, Cushing's disease, hepatic insufficiency, ankylosing spondylitis, rheumatoid arthritis, malnutrition/malabsorption, multiple myeloma and anaemia.
2. Use of medications such as corticosteroids, anticoagulants, chemotherapy, anticonvulsants, exogenous thyroid hormone having effects on bone metabolism.

3. A history of fracture, radiotherapy, implant placement or local bone destructive lesion in the region of interest (mandible, lumbar vertebrae, femoral neck, radius and ulna).
4. A history of smoking and/or alcoholism.
5. Previously diagnosed osteoporosis and/or using bone active medications such as calcitonin, bisphosphonates, fluorides, hormone replacement therapy, calcium, vitamin D.

The study was approved by local ethical committee and informed consent was obtained from all patients.

Panoramic radiography

Panoramic radiographs were taken by a single experienced operator on a Planmeca PM 2002 EC Proline panoramic x-ray unit using Kodak T-mat G/RA panoramic films with Kodak Lanex regular screens (Eastman Kodak Company, Rochester, New York). Exposure parameters used were 6-10 mA, 62-66 kV with an exposure time of 18 seconds. Exposed panoramic radiographs were processed manually and viewed flat using a viewing box placed on a table in a room with subdued lighting.

Quantitative indices

From each of the panoramic radiographs, right and left mental foramina, inferior cortex and cortices of antegonion and gonion were traced on acetylene tracing paper using a 4B pencil. From these tracings, measurements were made in millimetres using a digital vernier caliper for quantitative indices (*Figure 1*).

Inferior panoramic mandibular index (IPMI) and superior panoramic mandibular index (SPMI)

IPMI and SPMI were determined using the formulae proposed by Benson *et al.* (1991) [6].

- IPMI is calculated by dividing the cortical thickness at the mental foramen region (MI) by the distance from the inferior margin of the mental foramen to the inferior border of the mandible (I).
- SPMI is calculated by dividing the cortical thickness at the mental foramen region (MI) by the distance from the superior margin of the mental foramen to the inferior border of the mandible (S).

Mental index (MI)

MI was determined as the measured width of the

inferior cortex at the mental foramen region (*Figure 1*) [7,8].

Antegonion index (AI)

AI was determined as the measured cortical width in the region anterior to the gonion at a point identified by extending a line of best fit on the anterior border of the ascending ramus down to the lower border of the mandible (*Figure 1*) [9].

Gonion index (GI)

For determining the location of gonion, a vertical tangent was drawn to the posterior border of ramus; the angle made by this line with the tangent to the lower border of the mandible at the mental foramen region was bisected and at a point of intersection of this bisector line with the angle of mandible, the thickness of angular cortex was measured (*Figure 1*).

For each of these indices, the index score for a patient was determined by calculating the mean of right and left side scores.

Qualitative index

Each panoramic radiograph was assessed for the mandibular cortical index (MCI).

Mandibular cortical index (MCI)

MCI was determined by observing the inferior cortex distal to the mental foramen on both sides of the mandible, using the criteria described by Klemetti *et al.* (1997) [10].

- C1: The endosteal margin of the cortex sharp and even on both sides of the mandible (*Figure 2*).
- C2: The endosteal margin with semilunar defects (resorption cavities) and cortical residues one to three layers thick on one or both sides (*Figure 3*).
- C3: The endosteal margin appearing clearly porous with thick cortical residues (*Figure 4*).

Each radiograph was reassessed independently for all the indices by another two experienced oral and maxillofacial radiologists who were trained in assessing the indices. Assessment of the indices by each of these observers was repeated after one week. One of the observers could not identify the mental foramen in two radiographs, the endosteal margin at antegonion in one radiograph, and the endosteal margin at the gonion in seven radiographs.

Dual energy x-ray absorptiometry examination

Using a standard procedure, a single experienced technician at the Centre for Osteoporosis and Metabolic Bone Disease, Nagpur, India, performed

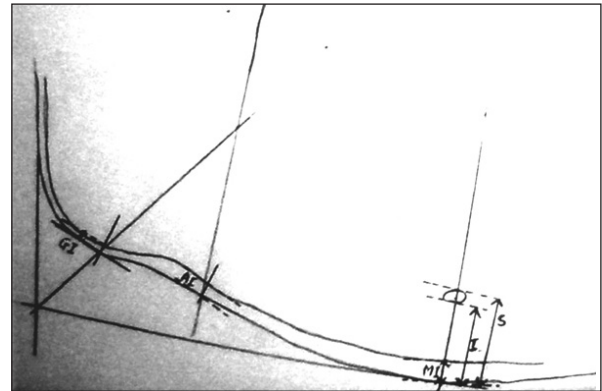


Figure 1. Measurements on panoramic radiograph for quantitative indices. MI = mental index, AI = antegonion index, GI = gonion index, I = distance from inferior margin of mental foramen to inferior border of mandible, S = distance from superior margin of mental foramen to inferior border of mandible.

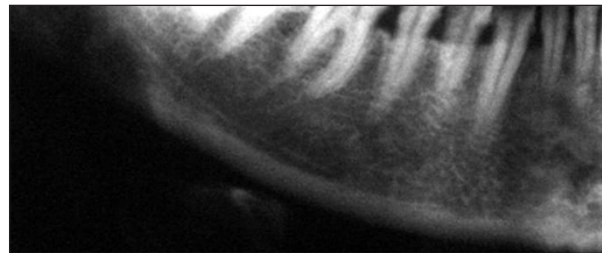


Figure 2. MCI category C1: The endosteal margin of the cortex sharp and even on both sides of the mandible.

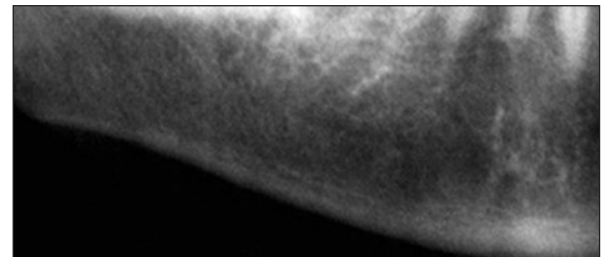


Figure 3. MCI category C2: The endosteal margin with semilunar defects (resorption cavities) and cortical residues one to three layers thick on one or both sides.

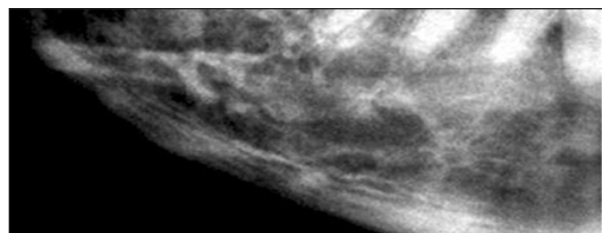


Figure 4. MCI category C3: The endosteal margin appearing clearly porous with thick cortical residues.

DXA scans of the lumbar vertebrae (L1-L4) and the left hip of all patients who took part in the study

using the Lunar DPX DXA system (GE Healthcare, Bangalore, India). Exposures were made at 1.5 mA and 76 kV. Scan time ranged from 3.5 minutes to 7 minutes. The scans were analysed by enCORE™ 2006 software (version 10.5) (GE Healthcare).

Bone mineral density (BMD) and T-scores obtained from the DXA scans were used to divide the patients into three categories using World Health Organization (WHO) criteria. According to these criteria, a subject is classified as having osteoporosis if the T-score of the lumbar spine is -2.5 or less. This diagnosis is considered as the gold standard [11].

DXA examination of the body of the mandible was performed using the methodology proposed by Horner *et al.* (1996) [4]. Forearm software was used, as no DXA software specifically designed for the mandible was available. For mandibular scanning, patients were positioned semi-prone, left side raised, with the neck slightly extended and the head in a true lateral position. The aim was to superimpose the contralateral sides of the mandible while avoiding superimposition of the cervical spine. Scanning was performed in a rectilinear manner, with a scan time of about 10 minutes, beginning 1 cm above the temporomandibular joints and continuing through the whole of the mandible.

To derive data for the mandibular BMD, a manual analysis was performed in which the rectangular customised region of interest (ROI) was placed over the body region. The shape and size of ROI was altered to conform to the shape of the bone image of each patient. In patients in whom superimposition of contralateral sides of the mandible had been imperfect, care was taken to position ROIs to cover only the superimposed areas (Figure 5).

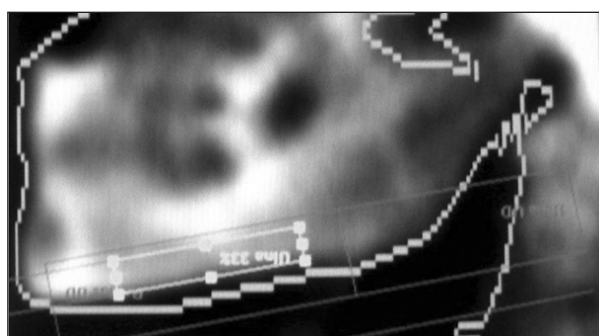


Figure 5. Mandibular DXA image with a region of interest, box placed over the superimposed sides of the mandibular body.

Statistical analysis was performed using statistical software (Statistical Package for the Social Sciences Version 14.0; SPSS Inc, Chicago, IL, USA). The data were expressed as the arithmetic mean and standard deviation. Pearson coefficients were used to analyse the relationship of mandibular bone mineral density (MBMD) and quantitative indices with BMD of lumbar vertebrae. Analysis of variance (ANOVA) and Sheffe analysis were used to analyse the differences of mean MBMD between groups C1, C2 and C3. The chi-square test was used to analyse the relationship of groups C1, C2 and C3 with normal/osteopenic and osteoporotic groups. The paired and unpaired *t*-tests were used to assess the intra- and inter-observer agreements, respectively, in determination of the quantitative indices. The kappa coefficient was used to assess the intra- and inter-observer agreements in determination of the MCI.

Results

In this study, 32 postmenopausal patients with an age range of 45 to 76 years (mean age 58.78 years) were examined. Mean age at menopause was 45.84 years. Mean body mass index (BMI) was 23.16 kg/m². Sixty-seven per cent of the patients were osteoporotic.

MBMD, as well as all the qualitative and quantitative indices, correlated negatively with age and with the time since menopause and positively with BMI. A significant positive correlation of MBMD was found with the BMD of lumbar vertebrae (L1 to L4) (Pearson correlation coefficient = 0.664, $P < 0.05$).

Of the 32 patients, the numbers of patients classified into groups C1, C2 and C3 were 10, 12 and 10, respectively. Only three women in the study group did not have osteoporosis and all of them showed cortical morphology consistent with group C1.

MBMD decreased from groups C1 to C2 to C3. However, the difference between groups C1 and C3 was statistically significant ($P < 0.05$) (Table 1). There was a significant ($P < 0.05$) association between MCI and osteoporosis; incidence of osteoporosis increased from group C1 to C2 to C3 (Table 2).

A strong positive correlation was observed between all quantitative indices and bone mineral densities of lumbar vertebrae (Table 3).

Table 1. Relationship of MCI with MBMD

MCI subgroup	Number of patients	Mean MBMD (g/cm ²)	Standard deviation	ANALYSIS OF VARIANCE (ANOVA)		
				F value	P value	Result
C1	10	1.7118	0.3877	9.387	<0.05	Significant
C2	12	1.5261	0.2171			
C3	10	1.2095	0.3441			
TOTAL	32	1.4852	0.3694			
MULTIPLE COMPARISONS BY SCHEFFE ANALYSIS						
MCI subgroup	MCI subgroup		P value		Result	
C1	C2		0.406		Non significant	
C1	C3		<0.05		Significant	
C2	C3		0.084		Non significant	

Table 2. Relationship between MCI and osteoporosis

	Normal/osteopenic	Osteoporotic	Total
C1	9 (2+7)	1	10
C2	2 (0+2)	10	12
C3	0	10	10
TOTAL	11 (2+9)	21	32
χ^2 value	20.622		
P value	<0.05		
Result	Significant		

Table 3. Relationship between quantitative indices and bone mineral densities of lumbar vertebrae

	MI	IPMI	SPMI	AI	GI
r	0.626	0.515	0.532	0.540	0.471
P value	<0.05	<0.05	<0.05	0.05	<0.05

r = Pearson correlation coefficient

For Observer 1, differences between the first and second observations of MI, IPMI, SPMI and GI were not statistically significant ($P>0.05$), suggesting a good intra-observer agreement, whereas the difference between the first and second observa-

tions of AI was statistically significant ($P<0.05$), suggesting a poor intra-observer agreement (Table 4).

For Observer 2, differences between the first and second observations of MI, IPMI, SPMI and AI were statistically significant ($P<0.05$), suggesting a poor intra-observer agreement, whereas the difference between first and second observations of GI was not statistically significant ($P>0.05$), suggesting a good intra-observer agreement (Table 4).

The means of the first and second observations of each observer for each index were calculated and were used for testing inter-observer variability. Differences between observations of MI, IPMI, SPMI were statistically significant ($P<0.05$), suggesting a poor inter-observer agreement, whereas difference between observations of AI and GI were not statistically significant ($P>0.05$) suggesting a good inter-observer agreement (Table 5).

For MCI, intra-observer agreement for Observer 1 was excellent ($\kappa>0.81$). Intra-observer agreement for Observer 2 was good ($0.80>\kappa>0.61$). Inter-observer agreement was also good ($0.80>\kappa>0.61$) (Table 6).

Table 4. Intra-observer agreement in determination of quantitative indices (paired t-test)

		MI		IPMI		SPMI		AI		GI	
		1st	2nd	1st	2nd	1st	2nd	1st	2nd	1st	2nd
Observer 1	Mean	4.1563	4.1227	0.3290	0.3233	0.2640	0.2610	2.4384	2.2068	1.2320	1.1876
	t value	0.305		0.397		0.302		2.350		0.665	
	P value	0.763		0.694		0.765		0.026		0.512	
Observer 2	Mean	3.7100	3.3710	0.3100	0.2730	0.2540	0.2227	2.2431	2.0553	1.3025	1.1856
	t value	2.952		3.033		3.289		2.2934		1.288	
	P value	0.006		0.005		0.003		0.029		0.207	

1st = First observation; 2nd = Second observation

Table 5. Inter-observer agreement in determination of quantitative indices (unpaired t-test)

	MI		IPMI		SPMI		AI		GI	
	1	2	1	2	1	2	1	2	1	2
Mean	4.1314	3.4827	0.3233	0.2886	0.2608	0.2353	2.3597	2.1492	1.2470	1.2441
t value	3.307		2.083		1.865		1.201		0.025	
P value	0.002		0.041		0.067		0.234		0.980	

1 = Observer 1; 2 = Observer 2

Table 6. Intra- and inter-observer agreement in determination of MCI

	κ	Observed agreement	SE	P value
Intra-observer (observer-1)	0.96	98.4%	0.038	<0.0001
Intra-observer (observer-2)	0.74	90.6%	0.1	<0.0001
Inter-observer	0.79	91.9%	0.087	<0.0001

κ = Kappa coefficient; SE = Standard error

Discussion

The choice of postmenopausal population for the study was based on the fact that osteoporosis is most prevalent in this population and therefore more likely to show osteoporotic changes on radiographs. The MBMD and various radiomorphometric indices correlated negatively with age and also with duration since menopause. This suggests that the bone loss increases with advancing age and that it accelerates after menopause. This is consistent with a previous finding that all the radiomorphometric indices correlated negatively with age [9]. Negative correlation of the MBMD and various indices with age is consistent with the fact that bone loss increases with advancing age [6,11].

Klemetti and Kolmakow (1997) have validated the choice of morphology of mandibular cortex on panoramic radiograph in assessment of bone quality rather than the trabecular bone or alveolar process [10].

The relationship between the MBMD and the MCI suggests that the MCI effectively reflects the changes in the MBMD measured by methodology proposed by Horner *et al.* (1996) [4]. The correlation between the MBMD and the MCI has also been reported by other investigators [10,12,14,15]. In the current pilot study, the MBMD, the MCI and all other quantitative indices correlated significantly with osteoporotic changes in the lumbar vertebrae. Many other investigators have reported similar findings [12,13,16-22]. Thus, the MCI as well as

quantitative indices reflects the osteoporotic changes in the mandible and may also give a clue of osteoporosis at other skeletal sites. Nevertheless, one earlier study did not find correlation between the MBMD and the BMD of other bones [17]. This may have been because the study concerned used different methods i.e., computed tomography for measurement of the MBMD and DXA for measurement of the BMD of the lumbar vertebrae [17].

Limited intra- and inter-observer agreement in the determination of quantitative indices observed in the present study can be explained by the difficulty in locating the endosteal margin of the cortex in the mental foramen region (due to presence of heavy cortical residues), inferior or superior margins of the mental foramen, the line of best fit on the anterior border of ramus, and/or endosteal margin in the antegonion region. Dutra *et al.* (2005) [23] also found limited intra-observer and inter-observer agreement in the measurement of these quantitative indices. In contrast, Ledgerton *et al.* (1997) [9] found good agreement. Recently, two separate studies [24,25] successfully used a computer-aided diagnostic system to assess the osteoporotic changes in panoramic radiographs. This newly suggested computer-assisted methodology may overcome the limitations of manual assessment of these quantitative indices.

As the exact identification of radiographic landmarks and precise measurements are not involved, the MCI is easy to determine, unlike in quantitative indices. This also explains the excellent intra-observer and inter-observer reproducibility for this index and thus establishes it as a useful tool in identifying osteoporotic individuals from panoramic radiographs. Excellent reproducibility of the MCI was also reported by many other investigators [9,14,19,26].

None of the available methods can diagnose osteoporosis in its early stages. Therefore all the methods are directed to predict the risk of osteoporotic fractures so that preventive measures can be initiated. DXA is currently considered as the gold stan-

dard in assessing such risk [27]. Radiographs depict the resorptive changes only after 30% loss of mineral content; this explains the finding that seven of ten individuals classified in group C1 had osteoporosis and the incidence further increased in groups C2 and C3. Thus, the MCI is unable to diagnose early stages of osteoporosis and it cannot be an alternative to DXA examination, but it can identify the individuals who can benefit from DXA examination, using the information already available in the dental office i.e., the panoramic radiograph.

Conclusion

From the small group studied, it can be concluded that the mandibular cortical index, a qualitative index based on morphological changes in the inferior cortex observed on panoramic radiographs, is a useful tool for the screening of postmenopausal osteoporotic patients. Quantitative indices (the mental index, inferior and superior panoramic mandibular indices, antegonion index and gonion index), although well correlated with skeletal bone loss, were not useful because of their poor reproducibility. A study with a larger sample is needed to confirm the results from this pilot.

References

- White SC. Oral radiographic predictors of osteoporosis. *Dentomaxillofacial Radiology*. 2002; **31**: 84-92.
- Krane SM, Holick MF. Metabolic bone disease: Osteoporosis. In: Wilson JD Braunwald E, editors. *Harrison's Principles of Internal Medicine*. Vol 2. 12th ed. New York: McGraw Hill; 1991. p. 1921-1926.
- Hildebolt CF. Osteoporosis and oral bone loss. *Dentomaxillofacial Radiology*. 1997; **26**: 3-15.
- Horner K, Devlin H, Alsop CW, Hodgkinson IM, Adams JE. Mandibular bone mineral density as a predictor of skeletal osteoporosis. *British Journal of Radiology*. 1996; **69**: 1019-1025.
- Aggarawal N, Raveendran A, Khandelwal N, Sen RK, Thakur JS, Dhaliwal LK, *et al*. Prevalence and related risk factors of osteoporosis in peri- and postmenopausal Indian Women. *Journal of Midlife Health*. 2011; **2**: 81-85
- Benson BW, Prihoda TJ, Glass BJ. Variations in adult cortical bone mass as measured by panoramic mandibular index. *Oral Surgery, Oral Medicine, Oral Pathology*. 1991; **71**: 349-356.
- Ledgerton D, Horner K, Devlin H, Worthington H. Panoramic mandibular index as a radiomorphometric tool: An assessment of precision. *Dentomaxillofacial Radiology*. 1997; **26**: 95-100.
- Gungor K, Akarslan ZZ, Akdevelioglu M, Erten H, Semiz M. The precision of the panoramic mandibular index. *Dentomaxillofacial Radiology*. 2006; **35**: 442-446.
- Ledgerton D, Horner K, Devlin H, Worthington H. Radiomorphometric indices of the mandible in a British female population. *Dentomaxillofacial Radiology*. 1999; **28**: 173-181.
- Klemetti E, Kolmakow S. Morphology of the mandibular cortex on panoramic radiographs as an indicator of bone quality. *Dentomaxillofacial Radiology*. 1997; **26**: 22-25.
- Verheij JCG, Geraets WVM, van der Stelt PF, Horner K, Lindh C, Nicopoulou-Karayianni K, *et al*. Prediction of osteoporosis with dental radiographs and age. *Dentomaxillofacial Radiology*. 2009; **38**: 431-437.
- Horner K, Devlin H. The relationships between two indices of mandibular bone quality and bone mineral density measured by dual energy X-ray absorptiometry. *Dentomaxillofacial Radiology*. 1998; **27**: 17-21.
- Taguchi A, Ohtsuka M, Nakamoto T, Naito K, Tsuda M, Kudo Y, *et al*. Identification of postmenopausal women at risk of osteoporosis by trained general dental practitioners using panoramic radiographs. *Dentomaxillofacial Radiology*. 2007; **36**: 149-154.
- Zlaticar DK, Celebic A. Clinical bone densitometric evaluation of the mandible in removable denture wearers dependent on the morphology of the mandibular cortex. *Journal of Prosthetic Dentistry*. 2003; **90**: 86-91.
- Drozdowska B, Pluskiewicz W, Tarnawska B. Panoramic based mandibular indices in relation to mandibular bone mineral density and skeletal status assessed by dual energy X-ray absorptiometry and quantitative ultrasound. *Dentomaxillofacial Radiology*. 2002; **31**: 361-367.
- Horner K, Devlin H. The relationship between mandibular bone mineral density and panoramic radiographic measurements. *Journal of Dentistry*. 1998; **26**: 337-343.
- Balcikonyte E, Balciuniene I, Alekna V. Panoramic radiographs in assessment of the bone mineral density.

Acknowledgement

The authors would like to thank the staff of the Department of Oral Medicine and Radiology for their cooperation.

Funding

There was no external source of funding. The cost of the study was borne by the authors themselves.

Contributions of each author

- PRB participated in the design, performing the examinations, coordinated the study and drafted the manuscript.
- RNM participated in the design, coordination and supervision of the study and drafted the manuscript.
- Both authors read and approved the final manuscript.

Statement of conflict of interest

The authors disclose no possible conflict of interest.

Stomatologija, Baltic Dental and Maxillofacial Journal. 2004; **6**: 17-19.

18. Drozdowska B, Pluskiewicz W. Longitudinal changes in mandibular bone mineral density compared with hip bone mineral density and quantitative ultrasound at calcaneus and hand phalanges. *British Journal of Radiology*. 2002; **75**: 743-747.

19. Yasar F, Akgunlu F. The differences in panoramic mandibular indices and fractal dimension between patients with and without spinal osteoporosis. *Dentomaxillofacial Radiology*. 2006; **35**: 1-9.

20. Kribbs PJ, Chesnut CH, Ott SM, Kilcoyne RF. Relationship between mandibular and skeletal bone in a population of normal women. *Journal of Prosthetic Dentistry*. 1990; **63**: 86-89.

21. Bras J, van Ooij CP, Abraham-Inpijn L, Kusen GJ, Wilmink JM. Radiographic interpretation of the mandibular angular cortex: A diagnostic tool in metabolic bone loss. *Oral Surgery, Oral Medicine, Oral Pathology*. 1982; **53**: 541-545.

22. Kim JY, Nah KS, Jung YH. Comparison of panorama radiomorphometric indices of the mandible in normal and osteoporotic women. *Korean Journal of Oral Maxillofacial Radiology*. 2004; **34**: 69-74.

23. Dutra V, Yang J, Devlin H, Susin C. Radiomorphometric indices and their relation to gender, age and dental status. *Oral Surgery, Oral Medicine, Oral Pathology, Oral Radiology and Endodontology*. 2005; **99**: 474-484.

24. Nakamoto T, Taguchi A, Ohtsuka M, Sueti Y, Fujita M, Tsuda M, *et al.* A computer-aided diagnosis system to screen for osteoporosis using dental panoramic radiographs. *Dentomaxillofacial Radiology*. 2008; **37**: 274-281.

25. Kavitha MS, Asano A, Taguchi A, Kurita A, Sanada M. Diagnosis of osteoporosis from dental panoramic radiographs using the support vector machine method in a computer-aided system. *BMC Medical Imaging*. 2012; **12**: 1-11.

26. Taguchi A, Sueti Y, Ohtsuka M, Otani K, Tanimoto K, Ohtaki M. Usefulness of panoramic radiography in the diagnosis of postmenopausal osteoporosis in women. Width and morphology of inferior cortex of the mandible. *Dentomaxillofacial Radiology*. 1996; **25**: 263-267.

27. Lentle BC, Prior JC. Osteoporosis: What a Clinician Expects to Learn from a Patient's Bone Density Examination. *Radiology*. 2003; **228**: 620-628.