

The Treatment of Recurrent Lymphangioma in the Oral Buccal Mucosa by Cryosurgery: A Case Report

Necdet Dogan¹, Can Engin Durmaz², Metin Sencimen¹, Ozlem Ucok³, Kemal Murat Okcu², Omer Gunhan⁴, Osman Kose⁵, Aydin Gulses⁶

¹ Ph.D., D.D.S. Associate Professor, Gülhane Military Medical Academy Department of Oral and Maxillofacial Surgery, Ankara, Turkey. ² Ph.D., D.D.S. Gülhane Military Medical Academy Department of Oral and Maxillofacial Surgery, Ankara, Turkey. ³ Associate Professor, Gülhane Military Medical Academy Department of Oral Diagnosis and Radiology, Ankara, Turkey. ⁴ Ph.D., D.D.S. Professor, Gülhane Military Medical Academy Department of Pathology, Ankara, Turkey. ⁵ Ph.D., M.D. Gülhane Military Medical Academy Department of Dermatology, Ankara, Turkey. ⁶ D.D.S. Gülhane Military Medical Academy Department of Oral and Maxillofacial Surgery, Ankara, Turkey.

Abstract

Aims: To present the case of a recurrent lymphangioma in the oral buccal mucosa and briefly discuss the treatment options of the condition. **Method:** The lesion was surgically ablated; nevertheless, it recurred two months following surgery. The recurrent lymphangioma was then treated very successfully with cryosurgery. **Result:** The patient has now remained asymptomatic for more than 12 months and experienced no recurrence following the cryosurgery. **Conclusion:** Cryosurgery is a safe and simple option in the treatment of lymphangiomas.

Key Words: Lymphangioma, Cryosurgery, Case Report

Introduction

Lymphangiomas are benign tumors of lymphatic vessels, which are localized in the head and neck area in about 75% of cases [1]. They manifest frequently at birth or before two years of age [2]. Lymphangiomas are also known to be associated with Turner syndrome, Noonan syndrome, trisomies, cardiac anomalies, and fetal alcohol syndrome [3].

Lymphangiomas usually involve the head, neck, and oral region [3]. When a lymphangioma occurs in the oral cavity, there is a marked predilection for the anterior two-thirds of the tongue [3], which often results in macroglossia [4]. Occurrence in other areas such as cheeks, lips, floor of the mouth, palate and gingiva has also been reported [4-6].

Although lymphangiomas are benign lesions, the involvement of vital structures or aesthetic and functional requirements may necessitate the treatment of these pathologies. [2]. In the past, various methods have been reported for the treatment of lymphangiomas. Procedures such as surgical exci-

sion, radiation therapy, cryotherapy, electrocautery, sclerotherapy, steroid administration, embolisation, ligation, and laser surgery have been proposed to treat lymphangiomas [7-9].

Complete surgical excision remains the most accepted treatment option when it is possible [10-12]. Fortunately, most adult lymphangiomas are encapsulated or partially circumscribed and thus surgical removal is facilitated [1]. For recurrent, residual, unresectable or surgically challenging tumours, pre-operative intralesional injections of sclerosing agents such as 25% dextrose, hypertonic saline, bleomycin, aethoxysklerol, or OK-432 (picibanil) are recommended [11]. However, the chances of recurrence following the surgery may be high (10% to 38%) and apparently are a result of inadequate tumour removal [13-16]. Furthermore, lymphangiomas are thought to be very suitable for treatment by cryosurgery because of their high fluid content and poor blood supply [17].

The following case report is of a patient with a previously surgically ablated, recurrent lymphan-

gioma in the buccal mucosa, which was successfully treated by cryosurgery.

Case Report

A 35-year-old healthy male presented to the Department of Oral and Maxillofacial Surgery of Gülhane Military Medical Academy, Etlik, Turkey, with a painless swelling of 18 months' duration inside his left cheek. He said he thought that the lesion had grown in size over the previous two months because he was biting it when he ate. An intraoral clinical examination revealed the presence of a bluish-purple coloured lesion, 2.5-3.0 cm in diameter, which was connected to the lower part of the left inside cheek (*Figure 1*). When the lesion was palpated, it was found that its colour was unchanged and no ischaemic area appeared. Considering the fibrotic appearance, 18 months' duration, and traumatic aetiology, the provisional diagnosis was that the lesion was benign and, possibly, a traumatic granuloma.

An incisional biopsy was performed and a histological examination revealed that the lesion was a lymphangioma. Complete surgical ablation of the lesion under local anaesthesia was planned. Local anaesthetic was administered and the encapsulated lesion was excised with a 5 mm wide band of surrounding healthy tissue. The excised tissue measured 3.0 x 2.0 x 2.0 cm in size (*Figure 2*). The surgical wound was left for secondary epithelisation (*Figure 3*). The excised area healed uneventfully. Histologically, the lesion was stained with haematoxylin eosin. An area of squamous metaplasia was found in the lesion and lymphatic spaces lay in the tissue stroma (*Figure 4*).

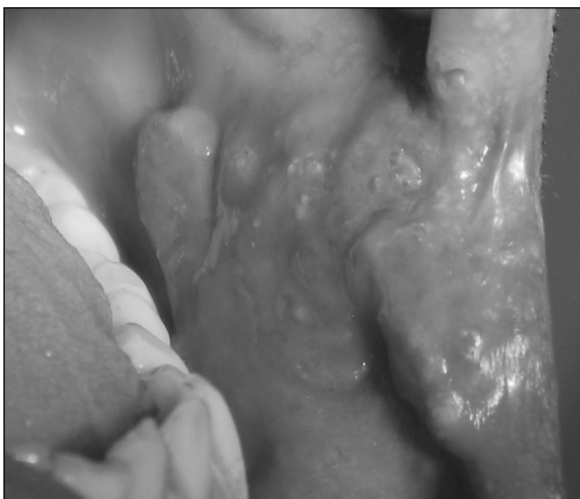

Figure 1. Intra-oral clinical appearance of the patient.

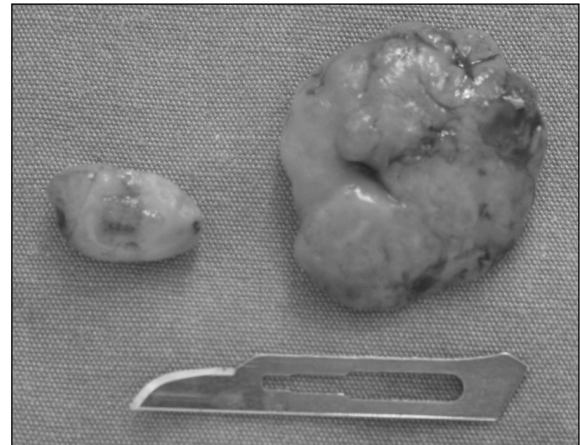


Figure 2. Excised specimens.

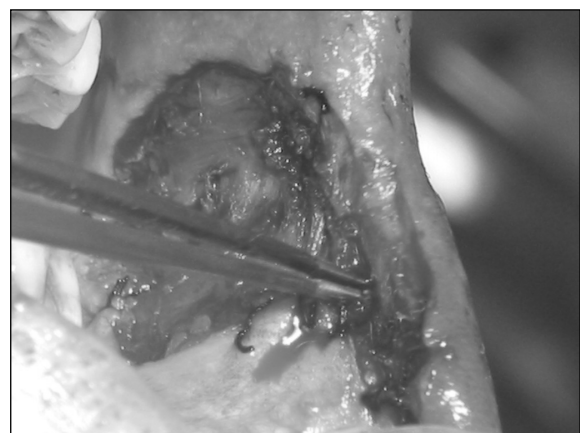


Figure 3. Surgical excision of the tumour.

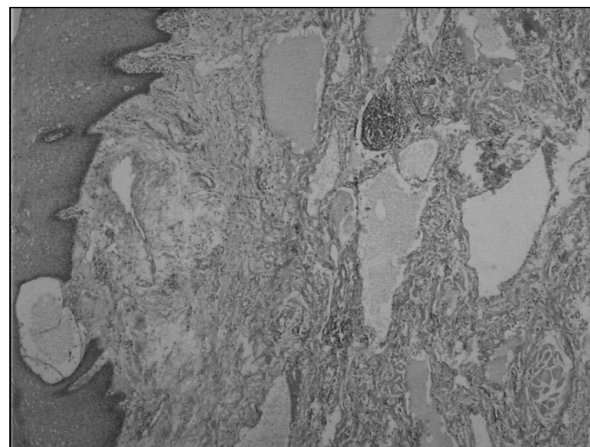


Figure 4. An area of squamous metaplasia was found on the lesion and lymphatic spaces lay in tissue stroma.

Two months following surgical excision, a recurrence was found on the buccal mucosa located near to the vermilion border (*Figure 5*). Instead of further ablative surgery, it was decided to treat the area with cryotherapy, which was given initially at monthly intervals. (*Figure 6*). Liquid nitrogen apparatus (CRY-AC; Brymill, Ellington, CT, USA) was used to perform the cryotherapy. Each session

consisted of a 20-second application time. During the first weeks, the clinical outcomes were satisfactory. However, a month after the first application, a new recurrence was noted on the same region. The recall time was reduced from one month to 15 days and following four cryotherapy applications, neither recurrence nor new pathologic changes was observed. At a one-year follow-up, pathology and recurrence were absent (*Figure 7*).

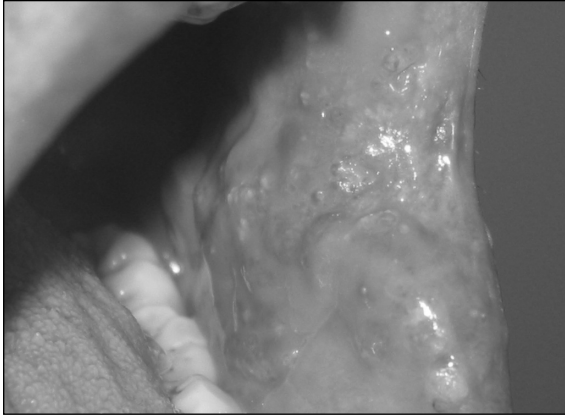


Figure 5. Recurrence two months following surgical ablation.

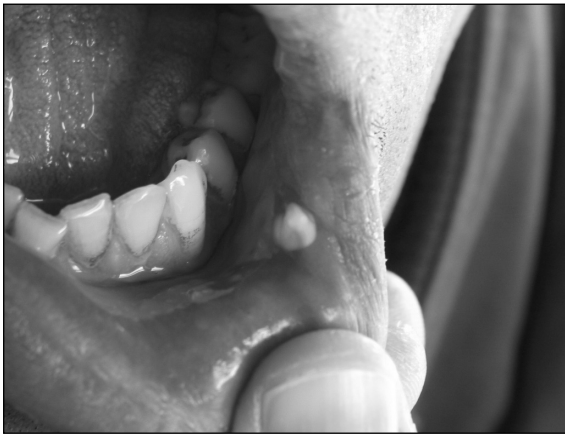

Figure 6. Cryosurgery applied area.

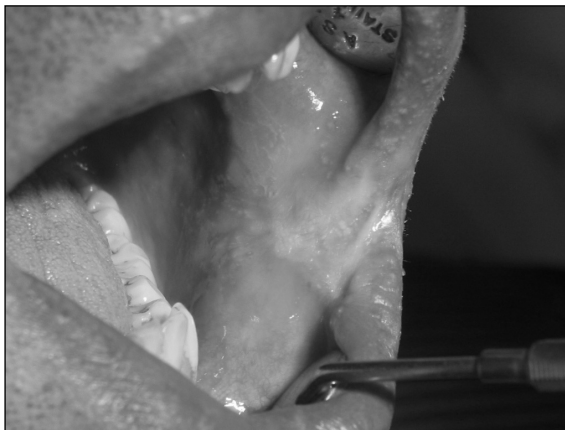

Figure 7. The patient experienced no recurrence during the 12 months following cryosurgery.

Discussion

Considering the complications related to their infiltrating nature—such as involvement of the adjacent anatomic structures, speech difficulties, respiratory distress, dysphagia and sleep apnoea—lymphangiomas may necessitate treatment [18]. The main options for treatment of lymphangiomas include surgical ablation, radiation therapy, electrocautery, cryotherapy, sclerotherapy, steroid administration, embolisation, ligation, and laser surgery.

Fortunately, most adult lymphangiomas are encapsulated or partially circumscribed and thus surgical removal is facilitated [10]. Therefore, surgical excision is the treatment of choice. However, encapsulation is not always complete and cellular infiltration of adjacent tissues becomes inevitable. Successful treatment requires the inclusion of a surrounding border of normal tissue, provided that vital structures are not damaged [13,14]. Additionally, the results following surgical ablation are often unsatisfactory because of the risks of complications, including damage to surrounding vital structures, nerves and blood vessels, prolonged lymphatic drainage from the wound, wound infections, and unacceptable scar formation [19,20]. Nevertheless, the chances of recurrence following the surgery may be high, (10% to 38%) and, as stated previously, are apparently a result of inadequate tumour removal [14-17].

Because of this, intralesional sclerosing agent injections such as sodium morrhuate, dextrose, hypertonic saline, tetracycline, doxycycline, acetic acid, ethanol, boiling water and OK-432 have been proposed [21]. The main advantage of OK-432 over other sclerosing agents is the absence of perilesional fibrosis, and intralesional injection of OK-432 has been proposed as the first-line treatment for lymphangioma for the past decade [22]. As a first-line therapy, complete regression was noted in 43.3% of cases [23]. However, in recent years, sclerotherapy is thought to be not as effective as previously reported and surgical excision after pre-treatment with sclerosing agent injections is recommended [16,22]. Furthermore, adverse reactions secondary to sclerotherapy such as fever, local swelling and hyperaemia at the injection site have been frequently reported [24].

Cryotherapy, also known as cryosurgery, is a commonly used in-office procedure for the treatment of a variety of benign and malignant lesions. The mechanism of destruction in cryotherapy is:

- Intracellular ice formation that leads to cell rupture.

- An increase in solute concentration within the damaged tissue.
- Inflammation in the damaged tissue.
- Vascular stasis in the area treated.

Following the application, treated areas re-epithelialise. Adverse effects of cryotherapy are usually minor and short-lived. Lymphangiomas are thought to be very suitable for treatment by cryosurgery because of their high fluid content and poor blood supply [17]. The treatment takes much less time compared to surgical excision [25]. Additionally, its effectiveness in eliminating pain is extremely important for palliative treatment [17].

References

1. Mandel L. Parotid area lymphangioma in an adult: case report. *Journal of Oral and Maxillofacial Surgery* 2004; **62**(10): 1320-1323.
2. Brennan TD, Miller AS, Chen SY. Lymphangiomas of the oral cavity: a clinicopathologic, immunohistochemical, and electron-microscopic study. *Journal of Oral and Maxillofacial Surgery* 1997; **55**: 932-935.
3. Neville BW, Damm DD, Allen CM, Bouquot JE. Soft tissue tumors. In: *Oral & Maxillofacial Pathology*. 2nd ed. Philadelphia, PA: WB Saunders; 2002: pp. 475-477.
4. Brennan TD, Miller AS, Chen SY. Lymphangiomas of the oral cavity. A clinicopathologic, immunohistochemical, and electron-microscopic study. *Journal of Oral and Maxillofacial Surgery* 1997; **55**: 932-935.
5. Morley SE, Ramesar KC, Macleod DA. Cystic hygroma in an adult. A case report. *Journal of the Royal College of Surgeons of Edinburgh* 1999; **44**: 57-58.
6. Shafer WG, Hine MK, Levy BM. Developmental disturbances of the tongue. In: *A Textbook of Oral Pathology*. 4th ed. Philadelphia, PA: WB Saunders; 1983: pp. 159-60.
7. Suen JY, Waner M. Treatment of oral cavity vascular malformations using the neodymium:YAG laser. *Archives of Otolaryngology—Head and Neck Surgery* 1989; **115**: 1329-1333.
8. Balakrishnan A, Bailey CM. Lymphangioma of the tongue. A review of pathogenesis, treatment and the use of surface laser photocoagulation. *Journal of Laryngology and Otology* 1991; **105**: 924-929.
9. Hellman JR, Myer CM, Prenger EC. Therapeutic alternatives in the treatment of life-threatening vasoformative tumors. *American Journal of Otolaryngology* 1992; **13**: 48-53.
10. Kennedy TL. Cystic hygroma-lymphangioma. A rare and still unclear entity. *Laryngoscope* 1989; **99**(Suppl 49): 1-10.
11. Mikhail M, Kennedy R, Cramer B, Smith T. Sclerosing of recurrent lymphangioma using OK-432. *J Pediatr Surg*. 1996; **31**:1463-4.
12. Brown RL, Azizkhan RG. Pediatric head and neck lesions. *Pediatric Clinics of North America* 1998; **45**: 889-905.
13. Fung K, Poenaru D, Sobeleski DA, Kamal IM. Impact of magnetic resonance imaging on the surgical management of cystic hygromas. *Journal of Pediatric Surgery* 1998; **33**: 839-841.
14. Schefter RP, Olsen KD, Gaffey TA. Cervical lymphangioma in the adult. *Otolaryngology—Head and Neck Surgery* 1998; **93**: 65-69.
15. Fraser SE, Campbell B, Kajdacsy-Balla A. Pathologic quiz case 2. Cystic lymphangioma. *Archives of Otolaryngology—Head and Neck Surgery* 1996; **122**: 893, 895.
16. Ricciardelli EJ, Richardson MA. Cervicofacial cystic hygroma. Patterns of recurrence and management of the difficult case. *Archives of Otolaryngology—Head and Neck Surgery* 1991; **117**: 546-553.
17. Bekke JP, Baart JA. Six years' experience with cryosurgery in the oral cavity. *International Journal of Oral Surgery* 1979; **8**: 251-270.
18. Dinerman WS, Myers EN. Lymphangiomatous macroglossia. *Laryngoscope* 1976; **86**: 291-296.
19. Kennedy TL, Whitaker M, Pellitteri P, Wood WE. Cystic hygroma/lymphangioma: a rational approach to management. *Laryngoscope* 2001; **111**: 1929-1937.
20. Emery PJ, Bailey CM, Evans JN. Cystic hygroma of the head and neck. A review of 37 cases. *Journal of Laryngology and Otology* 1984; **98**(6): 613-619.
21. Molitch HI, Unger EC, Witte CL, vanSonnenberg E. Percutaneous sclerotherapy of lymphangioma. *Radiology* 1995; **194**(2): 343-347.
22. Okazaki T, Iwatani S, Yanai T, Kobayashi H, Kato Y, Marusaka T, et al. Treatment of lymphangioma in children: our experience of 128 cases. *Journal of Pediatric Surgery* 2007; **42**(2): 386-389.
23. Acevedo JL, Shah RK, Brietzke SE. Nonsurgical therapies for lymphangiomas: a systematic review. *Otolaryngology—Head and Neck Surgery* 2008; **138**: 418-424.
24. Okada A, Kubota A, Fukuzawa M, Imura K, Kamata S. Injection of bleomycin as a primary therapy of cystic lymphangioma. *Journal of Pediatric Surgery* 1992; **27**: 440-443.
25. Dawber R, Colver G, Jackson A. *Cutaneous Cryosurgery. Principles and Clinical Practice*. 2nd ed. London: Martin Dunitz; 1997; pp. 4-30.
26. Regezi JA, Sciubba J. *Oral Pathology: Clinical-Pathologic Correlations*. 2nd ed. Philadelphia, PA: WB Saunders; 1993: pp. 214-216.
27. Sato M, Tanaka N, Sato T, Amagasa T. Oral and maxillofacial tumours in children: A review. *British Journal of Oral Maxillofacial Surgery* 1997; **35**: 92-95.
28. Park YW, Kim SM, Min BG, Park IW, Lee SK. Lymphangioma involving the mandible. Immunohistochemical expressions for the lymphatic proliferation. *Journal of Oral Pathology and Medicine* 2002; **31**(5): 280-283.

Conclusions

In conclusion, total surgical excision is generally recommended for the treatment of lymphangiomas [26-28]. Therefore, in the current case, in the first instance, complete surgical ablation of the lesion was performed. Following a recurrence, the patient did not undergo further surgery. The less invasive option of cryosurgery was employed to achieve a successful outcome.

This case highlights the advantages of cryosurgery in that it takes much less time and is much more effective in eliminating pain, compared to surgical excision. In the opinion of the authors, it is a safe and simple option in the treatment of lymphangiomas.