

Contributions to the elaboration and application of an objective codified index of evaluation of the dental pathological abrasion

Carmen Biriş, Lucian Ieremia, F. Berneanu

Târgu Mureş, România

Summary

The authors have elaborated a codified objective index which is the base of a computerized program with the purpose of validating the gravity of the pathological dental abrasion and the possibility of appreciation of the evolution stages, implying not only the character of the structural loss (enamel, enamel and dentine, dentine) but also a *number of etiological risk factors*, in the first position being the night-bruxism.

This means of investigation proves to be efficient not only in the clinical cases analyzed but also in the research carried on the skulls collection of the Anthropological Research Institute "Francis I. Rainer" of the National Romanian Academy in which the *used index has been integrated* in the combination of two methods: the gnathological and the craniometrical method.

Keywords: abrasion, index, computerized program.

Introduction

In the context of the technological and scientific development of the present times, dominated by the nuclear physics, electronics, cybernetics, genetics and the implementation of the computerized informatics in all activity fields, **Gnathology** has also taken a spectacular development. It has left an important mark in **Dental Medicine** by integration in **Human Biology** [1], [2].

As a result of improving our own prophylactic methodology, based on the utilization of multiple methods of investigation: epidemiological (corroborating the anamnestic findings with the objective ones), clinical, paraclinical and psychological methods, *new perspectives were opened* in the right formulation of the functional or dysfunctional status of the oro-facial system. (O.F.S). This malfunction state is conditioned by a number of etiopathogenical risk factors and it can have an influence over other biosystems of the body, *favoured or not*

by the presence of other systemic disease. [3]

This kind of medical vision with a well defined intersystemic interest has validated the existence of a correlation between the dental arches morphology (especially of the occlusal relief), the kinematics of the TMJ and the *isotonic-isometric contraction cycles* of the neuromuscular complex, coordinated by the central nervous system (C.N.S.), assuring in this way an optimal static and dynamic gearing of the teeth in favor of the homeostatic maintenance of the system.

As time passes, the primal sheer dental arch morphology suffers modifications as a result of the structural loss process which slowly and progressively takes place, transforming it in a secondary morphology. This situation imposes the distinction between the two clinical forms of abrasion: **the physiological form (attrition) and the pathological one** [4].

This pathological form of abrasion, by

compromising the occlusal relief, becomes a pathogenical risk factor for the oro-facial system, most of the times the crown-body deterioration being generated by: bruxism, low quality of the hard dental tissue that can be due to *the presence of a systemic disease*, biterminal partial edentation that has not been treated and which obliges the patient to use in mastication only the frontal teeth and last but not least the traumatological occlusion (T.O) caused by the pathological abrasion through metal-ceramic crowns that can also *modify the vertical occlusion dimension (V.O.D.)*.

In the specific literature, it has been noticed that in the patients with V.O.D. modification, the dysfunction of the oro-facial system is mostly caused by the eccentric clinical form of the bruxism (night bruxism) [5,6,7]. Quoting E. S. Brown and Hong [8], in other cases the nighttime clashing of teeth can occur in mentally disturbed patients on antidepressive medication, or on the preexistent background of other nervous disease.

As a result of the isometric muscular contractions that contribute to the strong friction and constriction of the teeth there can appear a syndrome that the French authors name as “Algo-dysfunctional syndrome” [9] that has as consequences the aggravation of the occlusal disharmony, also including here the traumatical stress of dental and periodontal units.

Referring to the clinical aspect, the pathological dental abrasion in the context of this malfunction can be generalized or localized, the tissue loss involving different degrees of allocation.

For those reasons and because of the need to fully appreciate the gravity of the evolution stages in dental tissue loss we have elaborated an objective codified index which have been used not only with clinical purposes but also in a series of studies we made on skulls at the Anthropological Research Institute “Francis I. Rainer” of the National Romanian Academy in Bucharest and which results were recently made known [10].

Methods

Table 1. The objective index presentation

	Upper Jaw	Lower Jaw
A. None of the teeth presents dental pathological abrasion	0 points	0 points
B. Partial detrition of the free edge in some of the frontal teeth involving enamel loss and partial dentine loss (<i>Figure 1</i>) [11]	1 points	1 points
C. Partial detrition of the free edge in all the frontal teeth involving enamel loss and partial dentine loss (<i>Figure 2</i>) [12]	5 points	5 points
D. Complete detrition of the free edge in some of the frontal incisors involving important dentine loss (<i>Figure 3</i>) (L. Ieremia's personal case)	10 points	10 points
E. Complete detrition of the free edge of all the frontal incisors involving important dentine loss (<i>Figure 4</i>) (L. Ieremia's personal case)	15 points	15 points
F. Partial detrition of the occlusal surface in some of the lateral teeth involving enamel loss and partial dentine loss	5 points	5 points
G. Partial detrition of the occlusal surface to all of the lateral teeth involving enamel loss and partial dentine loss (<i>Figure 5</i>) (L. Ieremia's personal case)	10 points	10 points
H. Complete detrition of the occlusal surface in some of the lateral teeth (the occlusal relief disappears) with excessive dentine loss (<i>Figure 6</i>) [12]	20 points	20 points
I. Complete detrition of the occlusal surface in all of the lateral teeth (the occlusal relief disappears) with excessive dentine loss	30 points	30 points

Observations:

- The patients with fixed prosthetic frameworks with the cemented crowns perforated on the occlusal surfaces will get a 20 points penalty and for the abrasion surfaces a 10 points penalty
- It is important if the dental abrasion is located only in the upper jaw or only in the lower jaw; in case that both upper and lower jaws are interested by abrasion the points allocated for B, C, D, E, F, G, H and I will be doubled.
- Regardless of the number of affected teeth, the points will be given for the dental

group to which the teeth are part of and to the specific of the dental loss, in this way resulting a larger number of clinical combinations of the dental abrasion.

Results and discussions

1. This objective index represents an efficient way to appreciate the gravity of the evolution stages of the pathological dental abrasion caused by a number of etiological risk factors, especially by the most destructive form of bruxism known as brucosis.

Table 2. The codification of the objective index of evaluation of the pathological dental abrasion

Negative result of pathological dental abrasion	0 points
Incipient pathological dental abrasion	1-10 points
Medium pathological dental abrasion	11-30 points
Severe pathological dental abrasion 1 st degree	31-60 points
Severe pathological dental abrasion 2 nd degree	More than 61 points

2. The correlation between multiple parameters in the form of our applied index give a coherent vision about different *types of dental abrasion* (twist drill type, ad palatum, ad linguam, horizontal), *the location of the abrasion surfaces* (regular, irregular or atypical), *the degree of dental structure loss* (only enamel, both enamel and dentine, dentine), *the extension of the structural loss* (isolated, extended on a specific perimeter of the dental arches, generalized destruction of the occlusal relief), *the pattern of the abrasion surfaces* (round form, oval form, with no precise form) and the *direction of the structural loss* (beveled or flat).

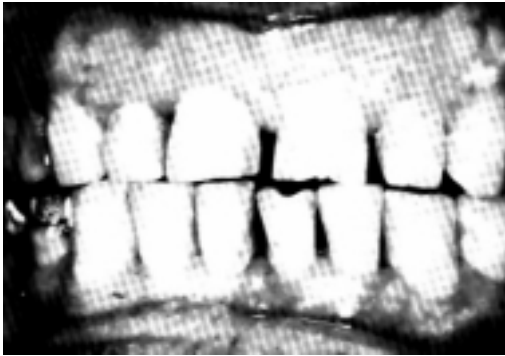3. As Rainer said [2], “every skull is the basement of the face”, we have applied successfully this index in a study over 422 complete, shortened or interrupted dental arches in 244 skulls, of which 192 were adult skull (2 from Stone Age – 12.000 years B.C;

3 from Feudal Age and 187 from Contemporary Age) and 52 were children skulls from the 20th century, part of the Francisc I. Rainer’s Romanian Academy collection.

Conclusion

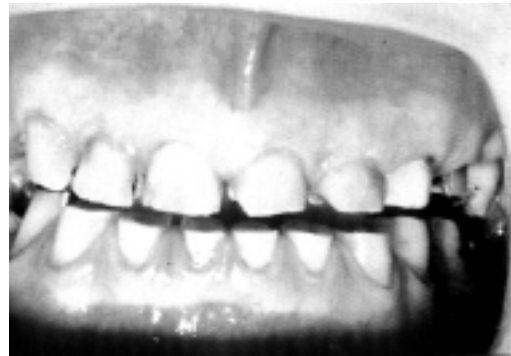In this way we have concluded that the skulls of the adults with pathological dental abrasion as compared to the skulls of the partial or complete edentulous older persons had different degrees of regressive reshaping of the hard components of the TMJ, in a progressive or in a combined form [10,2]. The results acquired in those researches will be the subject of another paper.

Figure 1.



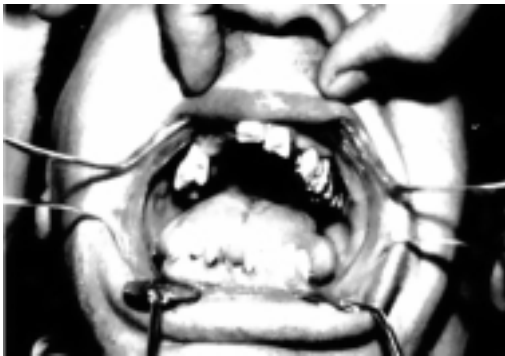Partial detrition of the free edge in some of the frontal teeth involving enamel loss and partial dentine loss

Figure 2.



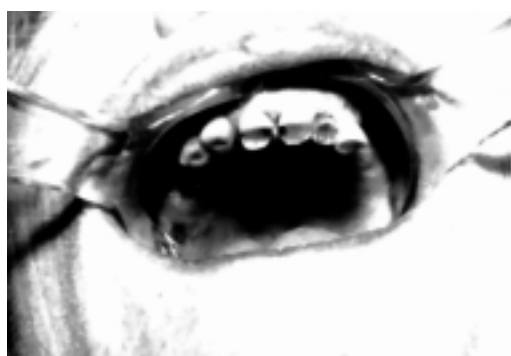Partial detrition of the free edge in all the frontal teeth involving enamel loss and partial dentine loss

Figure 3



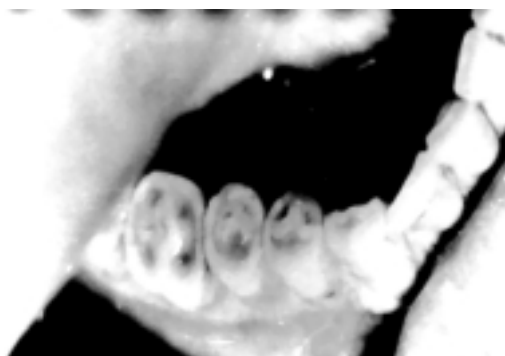
Complete detrition of the free edge in some of the frontal incisors involving important dentine loss

Figure 4



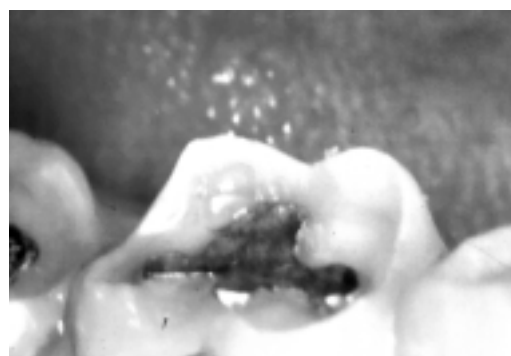
Complete detrition of the free edge of all the frontal incisors involving important dentine loss (L. Ieremia's personal case)

Figure 5.



Partial detrition of the occlusal surface in all of the lateral teeth involving enamel loss and partial dentine loss (L. Ieremia's personal case)

Figure 6



Complete detrition of the occlusal surface in some of the lateral teeth (the occlusal relief disappears) with excessive dentine loss

References

1. Ieremia L, Bratu D, Negruțiu M: *Metodologia de examinare în protetica dentară* (Examination methodology in dental prosthetics) – in Romanian. Ed. Signata, Timișoara, 2000.
2. Biriș C: Cercetări complexe diferențiate privind consecințele abraziiei dentare fiziologice și a celei patologice asupra sistemului stomatognat (Complex differentiated research regarding the consequences of physiological and pathological dental abrasion on the stomatognathic system) – in Romanian. Teză de doctorat, 2005 (PhD thesis, 2005). Facultatea de Medicină Dentară, UMF Târgu-Mureș. Conducător științific: Prof. univ. cons. Dr. Șt. Med. Lucian Ieremia.
3. Ieremia L, Chirilă Mioara Bălaș: *Gerontognatoprotetică. Elemente fundamentale și applicative* (Gerontognathoprosthetics. Basic and applied elements) – in Romanian. Ed. University Press, UMF Târgu-Mureș, 1999.
4. Ieremia L, Biriș Carmen, Horga C: Uzura dentară, leziune coronară cu pierdere structurală progresivă de natură necarioasă sau netraumatică (Dental wear, crown lesion with progressive structural loss of non-carious and nontraumatic origin) – in Romanian. *Revista Stomatologia Mureșană*, 2001b; II(2-3): 79-88.
5. Lobbezoo F, Lavigne G: Do bruxism and temporomandibular disorders have a cause and effect relationship? *J. of Oral Rehabil.*, 1998; **25**(9): 15-23
6. Miller VJ, Yoeli Z, Barnea E, Zeltser C: The effect of parafunction on condylar asymmetry in patients with temporomandibular disorders. *J. of Oral Rehabil.*, 1998; **25**(9): 706-714.
7. Ieremia L, Popșor S, Horga C, Biriș C, Suciuc M, Fokt I: Actualități privind particularitățile clinice ale bruxismului excentric (nocturn) cu implicații nocive asupra sistemului stomatognat (Up-to-dates regarding the clinical features of nocturn bruxism, with noxious implications on the stomatognathic system) – in Romanian. *Revista Stomatologia Mureșană*, 2001a; II(1): 29-33.
8. Brown ES, Hong SC: Antidepressant induced bruxism successfully treated with gabapentin. *J. of Dent. Assoc.*, 1999; **130**(10): 1467-1469
9. Gola R, Chossengros C, Orthlieb JD: *Syndromul Algo-Disfonctionnel de l'appareil Manducateur*. Ed. Masson, 2eme Edition, Paris, 1995.
10. Ieremia L, Biriș C, Totolici D, Glavce C: Remodelarea articulațiilor temporo-mandibulare. Elemente de fiziologie și fiziopatologie. (Remodelling of temporomandibular articulations. Elements of physiology and physiopathology) – in Romanian; conference. Comunicare-conferință susținută la 12 mai 2004 în cadrul Academiei Române, Centrul de Cercetări Antropologice, București.
11. Ramfjord SP, Ash MM: *L'Occlusion*. Ed. J. Prêlat, Paris, 1975.
12. Dahl B L, Oilo G: *Abrasion des dents et des matiaux de restauration*. In: Öwal B; Kyser AF; Carlsson GE: *Prothèse Dentaire. Principes et stratégies thérapeutiques*. Ed. Masson, Paris, Milan, Barcelone, 1998.

Correspondence to: Dr. Carmen Biriș, University of Medicine and Pharmacy Tg-Mures, Department of Prosthetic dentistry and Oral Rehabilitation; Str. Gh. Marinescu no. 38. E-mail: chiccacarmen@zappmobile.ro