

## **Role of titanium mesh as a reconstruction material for orbital floor defects in cases of orbital blowout trauma**

**Hamada mahran\***, **moayad alomaym \*\***, **salma albaty \*\*\***

### **ABSTRACT**

#### **Aim**

The purpose of this study is to evaluate the use of titanium mesh as a reconstruction material in cases of orbital blowout fractures, and its advantages, disadvantages.

#### **Methods:**

From January 2014 to December 2016, 24 patients with orbital blowout fractures managed surgically using titanium mesh were evaluated for improvement, degree of success, persistence of symptoms, complications. The recorded data included age, gender, cause of trauma, diplopia, enophthalmos, ocular motility, preoperative and postoperative orbital CT, preoperative and postoperative ophthalmological evaluation.

#### **Results:**

15 of 24 were males and 9 of 24 were females. motor vehicle accident was the most common cause of trauma, aggression was the second cause, industrial injury was the third cause. 11 of 12 patients with diplopia improved and one patient had persistent diplopia. All patients with enophthalmos or ocular motility disorders improved, only one patient developed late enophthalmos and treated using iliac bone graft. Titanium mesh was highly effective for sealing of orbital wall defects, improvement of symptoms, with no major complications.

#### **Conclusion:**

Titanium mesh is a good orbital reconstruction material, avoiding a lot of the drawbacks of autogenous sources such as bone and cartilage.

\*lecturer of maxillofacial surgery, general surgery department, faculty of medicine, Assiut university, Egypt

\*\*resident of oral and maxillofacial surgery, ministry of health, Saudia Arabia

\*\*\*resident of oral and maxillofacial surgery, ministry of health, Saudia Arabia

### **INTRODUCTION**

Orbital fractures account for 30 to 55% of all facial fractures. The most frequent etiology varies according to gender: in men, these fractures are more frequently the result of aggression, whereas in women, the frequent cause is an accidental fall. Fractures can be classified differently according to the degree of displacement (1), the degree of gravity and the fracture pattern (2), the degree of segmentation and comminution (3), and the strength applied against the bone (4), as well as according to the combination of their location, the number of fragments and the soft tissues affected (5).

The most outstanding feature that distinguishes blowout fractures from other maxillofacial fractures is the way that they fragment like egg-shells, and there is a need for a suitable material to reconstruct the orbital floor. The ideal material should be thin, light, enduring, easily shaped, and radiopaque but not be prone to infection that could interfere with further investigations (6). It should also not be carcinogenic and have no potential for transmission of disease (7).

Autografts, allografts, and alloplastic materials are used to reconstruct the orbital floor, but there is no consensus on which material is the best. (8,9,10,11)

The most important complications of alloplastic materials are infection, foreign body reaction, and exposure (12,13). Also alloplastic materials such as titanium mesh has been traditionally limited to transfacial approaches (14).

The biggest disadvantages of allografts are their potential for transmitting disease and their cost (15). Several donor sites have been described for autologous grafts, but the extended duration of operation, donor site morbidity and resorption of the graft, has limited their use (16). However, several studies have shown the reliability and safety of titanium in reconstructing internal orbital defects (17,18)

Titanium has excellent biocompatibility and demonstrates integration in adjacent bone, which results in low infection rate and rare postoperative migration of implants after titanium reconstruction. Titanium can be contoured to fit virtually any internal orbital defects because of its significant tensile strength and malleability. In addition, titanium is easily visualized on postoperative CT. These characteristics determine titanium to be well established as an implant material in orbital and adjacent craniofacial skeleton reconstruction. (19)

## **MATERIALS AND METHODS**

This is retrospective study carried out on 24 Egyptian patients, diagnosed with unilateral orbital blowout fractures, between January 2014 and December 2016, at Assiut university hospital. Five patients (21%) had isolated orbital blowout fractures (pure blowout fracture), Nineteen patients (79%) had associated orbital rim and midfacial fractures (impure blowout fracture). We excluded patients with bilateral orbital blowout fractures (to compare the injured side to the normal one), patients with severe panfacial comminution, patients younger than 18 years old and patients with orbital blow in fractures. Complete head and neck examination (including full ophthalmological evaluation pre & postoperative) was routine for all patients. Facial computed tomography (CT scan) (fig 1,3,4,5) was Performed for all patients (preoperative and postoperative). Patients were classified according to their CT examination into pure orbital blowout fracture (fracture of the orbital floor and/or the medial wall with intact orbital rims), and impure orbital blowout fracture (associated orbital rim fractures). All patients data were collected such as their ages, gender, cause of trauma, side of injury.

The indications for surgical interference were presence of diplopia, enophthalmos, entrapped muscles, CT evidence of a big orbital floor defect (more than half of the orbital floor).

## **SURGICAL TECHNIQUE**

The procedure was undertaken general anesthesia, within 5-10 days after trauma. The surgical approach was subciliary in 18 patients and direct on infraorbital rim (subtarsal) in 6 patients, this depends on the fracture site and the surgeon preference, leaving both eyes uncovered. Dissection up to the infraorbital rim, opening periosteum and subperiosteal dissection deep to orbital floor, deep in the orbit a malleable retractor is used to elevate the orbital tissues and improve visibility to properly identify the orbital fracture defect, reduction of the herniated orbital contents from side to side avoiding penetration of the orbital tissues, identification of stable defect borders to support the mesh, manipulation of the mesh to fit size, shape and completely cover the defect, careful attention must be paid to simulate the curves and slopes of the floor and medial wall (fig 2), thorough three-dimensional understanding of the complex anatomy of the bony orbit is a must to use this technique, the size of the mesh should not be much larger than the defect as it can affect globe motility and position, fixation of the mesh by screws to the orbital margin, proper periosteal closure is necessary, forced duction test was done for all cases before surgical closure of the incision (to make sure of total release of the herniated orbital tissues).

All patients received postoperative dexamethasone 5mg q8 hourly for 3 days postoperatively (if not contraindicated) Postoperative check CT done for all patients.

## RESULTS

During the period of this study, 24 orbits were reconstructed by titanium meshes. Fifteen patients (62%) were males, nine patients (37%) females. The age range from 18 to 66 years old. Motor vehicle accident was the most common cause (71%), aggression was the second cause for (21%), sport injury for one case (4%), industrial accident for one case (4%) .

Surgical outcomes were summarized in table 1. All patients with preoperative diplopia improved postoperatively except one case had persistent diplopia for four months postoperatively and the patient referred to higher center for possible revision.

All cases with preoperative enophthalmos improved clinically (by achieving clinically visible symmetric eyeball projection after surgery ) and as detailed by ophthalmological evaluation , but one case developed late enophthalmos (after six months, his CT revealed proper position of the mesh with good sealing of the defect but he had atrophy of the retrobulbar fat and this patient needed second surgery and revision done with placement of autogenous iliac bone graft and the patient improved . All cases diagnosed by CT as large orbital floor defect improved completely by comparing preoperative and postoperative CT scans.

Patients with definite muscle entrapment improved with no evidence of restriction of globe movement.

One patient with lower eyelid incision(subtarsal approach) developed ectropion and revised by secondary lid surgery and improved, but all patients with subciliary approach Improved without any approach related complications.

There were no intraoperative complications such as damage to the globe or the optic nerve or unexpected hemorrhage.

There were no postoperative complications like bleeding, vision loss, infection, implant extrusion, or malposition, orbital congestion, epiphora. All postoperative CT scans showed well positioned titanium meshes and maintenance of the floor reconstruction (fig 3, 4, 5).most of patients were satisfied with their final results and function.

Table1; Number of operated cases according to their symptoms

Indication of surgery	Number of patients	Number of improved cases	Persistence of Symptoms
Diplopia	12	11	1
Enophthalmos	8	8	0
Muscle entrapment	2	2	0
Huge orbital floor defect	2	2	0

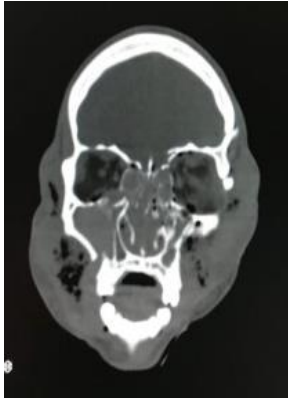


Fig 1: Preoperative Coronal CT view

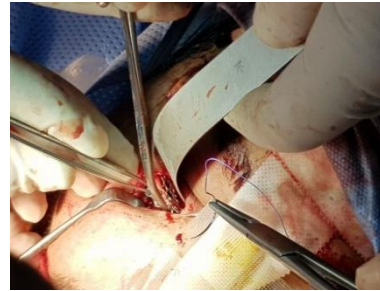

Fig 2: Intraoperative view

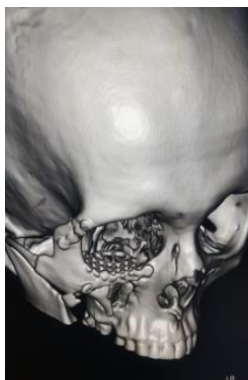

Fig 3: Post Op 3D view

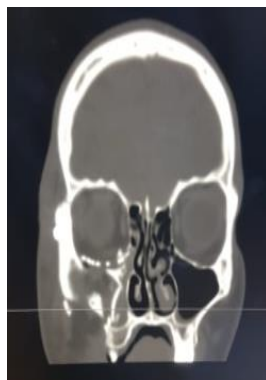

Fig 4: Coronal View Post Op

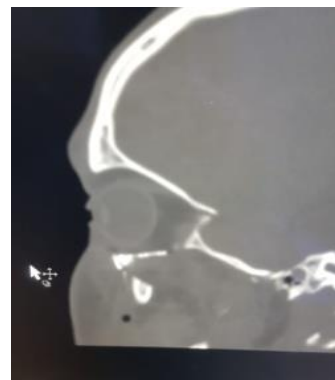


Fig 5: Sagittal View Post Op

## DISCUSSION

Since orbital floor fracture was first described by Lang in 1889, the most suitable material for reconstruction of the orbital floor has been controversial, and different authorities have suggested different materials. (20)

Although bone has good strength, no sharp edges, can be fixed to adjacent bone and is radiopaque, it can have a variable degree of resorption that can be problematic, and its lack of pliability creates a significant difficulty for adequate molding into complex shapes (21). The calvarium, iliac crest, nasal, maxillary and mandibular bone have been used as donor sites, with the first two being the most commonly used (22).

The main disadvantages of autologous materials are donor site morbidity, and the prolonged duration of the operation. Theoretically, alloplastic materials are of limited use because of complications such as foreign body reaction, infection and exposure, obstruction of the lacrimal canal, retrobulbar hemorrhage, oculomotor nerve palsy, high cost and difficulty in obtaining, shaping and contouring them. (23)

With respect to materials, titanium mesh can be easily fixed with little incidence of slippage. However titanium mesh is hard and iatrogenic injury is likely to occur if it is not appropriately implanted (24,25). We used titanium mesh to repair orbital floor defects and titanium plate to repair fractures of the orbital margin, consequently, no complications of iatrogenic injury, infection, discharging and displacement were reported.

Only one case developed persistent diplopia, and was referred to higher center, that means that the reconstruction material has no relation to development of persistent diplopia, in this we agree with Boyette JR, et al, who mentioned that, the frequency of persistent postoperative diplopia varies between 8 and 42%, and causes of persistent diplopia are muscle trauma and fibrosis, and paresis of the oculomotor nerves. (26)

All patients with preoperative enophthalmos improved as detailed by ophthalmological evaluation. But one patient presented six months later by late enophthalmos, his CT revealed that titanium mesh is in place, defect is sealed completely, ophthalmological consultation reported atrophy of the retrobulbar fatty tissue and advised reinforcement by a retroequatorial bone graft, iliac bone graft used to augment the orbital floor and the patient improved.

Postoperative intraorbital hematoma is a very rare complication, and some studies have recommended the placement of a negative pressure drain to prevent it (27). In this study, we did not use a negative pressure drain and none of our cases had intraorbital hematoma.

Regarding the surgical approach, we found that the subciliary approach is better than subtarsal approach, with less associated rate of approach related complications (ectropion, obvious scars), however some authors prefer the more aesthetic trans-conjunctival approach but it needs additional lateral canthotomy especially in extensive fractures (28). Recently Suzuki et al, applied the endoscopic approach to the orbital floor and medial wall. This technique has increased, as surgeons try to avoid eyelid complications and improve visualization of the orbital walls; however the transcutaneous approaches are more predictable for managing orbital floor fractures. (29,30).

Titanium is highly biocompatible, easily adjusted to architecturally fit simple and complex orbital defects, provides strong support, does not alter its shape or location over time, and it can be easily fixed to adjacent bone. It has well recognized osseointegration,

is easily sterilized and readily available, although at high cost. Unfortunately, the holes in the plates allow tissue ingrowth that may make removal more difficult, and the cut edges are prone to snaring periorbital soft tissue during placement. (31).

The use of titanium implants for reconstruction of orbital floor defects can greatly improve the aesthetic and functional outcomes, so it is considered one of the best options for orbital floor reconstruction.

## REFERENCES

- 1-Fonseca RJ:Orbital trauma .in :Oral and Maxillofacial Surgery :Trauma .Volume 3.Philadelphia . WB Saunders .2000.p 205
- 2-Jackson IT:Classification and treatment of orbitozygomatic and orbitoethmoid fractures . The place of bone grafting and plate fixation .Clin Plast Surg 16:77,1989
- 3-Zingg M,Laedrach K,Chen J,et al:Classification and treatment of zygomatic fractures :A review of 1.025 cases .J Oral Maxillofacial Surg50:778,1992
- 4-Manson PN,Markowitz B,Mirvis S,et al: Toward CT-based facial fracture treatment . Plast Reconstr Surg 85:202, 1990
- 5-Buitrago-Tellez CH,Schilli W, Bohnert M,et al:A comprehensive classification of craniofacial fractures :Postmortem and clinical studies with two-and three-dimensional computed tomography .Injury 33:651,2002
- 6-Sugar AW,Kuriakose M, Walshaw ND.Titanium mesh in orbital wall reconstruction . Int J Oral Maxillofac Surg 1992;21:140-4.
- 7-Baumann A, Burggasser G,Gauss N, et al . Orbital floor reconstruction with an alloplastic resorbable polydioxanone sheet.Int J Oral Maxillofac Surg 2002;31:367-73.
- 8-Nguyen NP,Sullivan P.Advances in the management of orbital fractures. Clin Plast Surg 1992;19:87-98.
- 9-Johnson PE,Raftopoulos I.In situ splitting of a rib graft for reconstruction of the orbital floor .Plast Reconstr Surg 1999;103:1709-11.
- 10-Harsha BC, Turvey TA, Powers SK.Use of autogenous cranial bone grafts in maxillofacial surgery : a preliminary report .J Oral Maxillofac Surg 1986;44:11-5.
- 11-Ono I, Gunji H,Suda K,et al . Orbital reconstruction with hydroxyapatite ceramic implants . Scand J Reconstr Surg Hand Surg 1994;28:193-8.
- 12-Takashima S, Tateishi J, Taguchi Y,et al . Creutzfeldt-Jacob disease with florid plaques after cadaveric dural graft in a Japanese woman .Lancet 1997;350:865-6.
- 13-Brown AE, Banks P. Late extrusion of alloplastic orbital floor implants .Br J Oral Maxillofac Surg 1993;31:154-7.
- 14-Gerbino G,Zavattero E,Viterbo S,et al. Treatment of orbital medial wall fractures with titanium mesh plates using retrocaruncular approach:outcomes with different techniques .Cranio-maxillofac . Trauma Reconstr 2015;8:326-333
- 15-Thadani V,Penar PL,Partington J,et al. Creutzfeldt-Jacob disease probably acquired from a cadaveric dura matter graft .Case report .J Neurosurg 1988;69:766-9.
- 16-Matsuo K,Hirose T, Furuta S,et al. Semiquantitative correction of posttraumatic enophthalmos with sliced cartilage grafts.Plast Reconstr Surg 1989;83:429-37.
- 17-Gear AJ ,Lokesh A,Aldridge JH, Migliori MR , Benjamin CI, Schubert W. Safety of titanium mesh for orbital reconstruction .Ann Plast Surg 2002;48(1):1-7
- 18-Sechon R,Metzger MC, Zizelmann C, Individually performed titanium mesh implants for a true-to-original repair of orbital fractures .Int J Oral Maxillofac Surg 2006;35(11)990-995
- 19-Garibaldi DC, Iliff NT, Grant MP, Merbs SL.Use of porous polyethylene with embedded titanium in orbital reconstruction:a review of 106 patients .Ophthal Plast Reconstr Surg 2007;23(6):439-444

- 20-Mathes SJ, editor Plastic Surgery ,2<sup>nd</sup> ed .Philadelphia :Saunders :2005.
- 21-Strong EB.Orbital fractures :pathophysiology and implant materials for orbital reconstruction .Facial Plast Surg 2014;30(5):509-517.
- 22-Guanarajah DR, Samman N.Biomaterials for repair of orbital floor fractures : a systemic review . J Oral Maxillofac Surg 2013;71(3):550-570.
- 23-Jordan DR, St Onge P, Anderson R ,et al. Complications associated with alloplastic implants used in orbital fracture repair .Ophthalmology 1992;99:1600-8.
- 24- Saragent LA,Fulks KD.Reconstruction of internal orbital fractures with Vitallium mesh .Plast Reconstr Surg 1991;88(1):31-38
- 25-Mackenzie DJ,Arora BA, Hansen J.Orbital floor repair with titanium mesh screen .J Craniomaxillofac Trauma 1999;5(3):9-16
- 26-Boyette JR ,Pemberton JD ,Bonilla –Velez J:Management of orbital fractures :Challenges and solutions ,Clin Ophthalmol 9:2127,2015.
- 27-Park CW, Yang JY, Son KM,Cheon JS:The estimation of postoperative bleeding after reduction of blowout fracture : The effectiveness of negative pressure drainage system . J Craniofac Surg 26:873.2015
- 28-Vaibhav N, Keerthi R, Nanjappa M, et al :Comparison of sutureless transconjunctival and subciliary approach for treatment of infraorbital rim fractures :A clinical study , J Maxillofac Oral Surg 15:355,2016.
- 29-Suzuki M, Nakamura Y, Ozaki S, Yokota M, Murakami S . Repair of orbital floor fracture with modified transnasal endoscopic approach through anterior space to nasolacrimal duct .J Craniofac Surg 2017;28(4):998-1002.
- 30-Beli E, Mici E, Mazonne N, Catalfamo L, Fini G, Liberatore GM. A monolateral TMJ replacement under intraoral endoscopic assistance for jaw osteomyelitis : A modified approach . G Chir 2015;36(1):36-9.
- 31-Ellis E 3<sup>rd</sup>, Tan Y. Assessment of internal orbital reconstructions for pure blowout fractures :cranial bone grafts versus titanium mesh . J Oral Maxillofac Surg .2003;61(4):442-453.